CASE REPORT

An unusual "tumor" of the cecum: the inverted appendiceal stump

SORINA TĂBAN[1)], ALIS DEMA[1)], DANIELA LAZĂR[2)],
I. SPOREA[2)], ELENA LAZĂR[1)], MARIOARA CORNIANU[1)]

[1)]*Department of Pathology*
[2)]*Department of Gastroenterology*
"Victor Babeş" University of Medicine and Pharmacy, Timişoara

Abstract

Intussusception of the appendix in adult represents an uncommon entity. We report a 54-year old woman who underwent an appendectomy 24 years previously and who was hospitalized for changes in bowel habits and periumbilical and epigastric pain. A sessile polypoid tumor of cecum was discovered during colonoscopy, which was removed. Histopathological examination showed that it was the case of an inverted appendiceal stump. Authors present reviews of the literature concerning clinical features, associated conditions, diagnosis, classification and therapy of this extremely rare condition.

***Keywords*:** intussusception, appendiceal stump, histopathological diagnosis.

Introduction

Intussusception of the appendix or of appendiceal stump is a very rare disease, with an incidence of 0.01% [1–3], and that is found more frequently in male children [4].

Only about 200 cases have been reported in the literature [5].

Despite of its rarity, this entity has to be preoperatively diagnosed [6], it being identifying as a cecal mass and very often mistaken for a tumor [1].

The nonspecific clinical features that may mimic acute or chronic abdominal diseases raise many problems for the positive diagnosis.

Case report

A 54-year old female, with duodenal ulcer in the past medical history was admitted for transit disturbances (alternation between constipation and diarrhea), 7 kg weight loss in eight months and epigastric and periumbilical pain.

Past medical history showed that the patient suffered an appendectomy in 1978. Physical examination revealed tenderness at the palpation in the epigastric and mesogastric region. Laboratory data does not show any significant changes. Total colonoscopy was normal, with the exception of a polyp-like sessile tumor at the appendiceal orifice, which measured 2 cm in length and 1 cm wide (Figure 1).

Endoscopic removal was undertaken during which the polyp was recovered (Figure 2).

Histopathological examination shows a polypoid lesion with the inversed structure of an appendix (Figure 3). The center of the lesion is represented by hyperplastic muscularis propria, with circular and longitudinal layers and myenteric plexus between of these two layers (Figure 4).

At the border of the muscular layer is submucosa with edem, congested vessels and the external surface of the polyp is covered by a mucosa with prominent lymphoid follicles (Figure 5).

An inflammatory infiltrate with lymphocytes, plasmocytes and especially eosinophils can be identifies in the lamina propria.

Discussions

In 1858, Mc Kid first described a complete invagination of the appendix into the cecum of a 7 year-old boy. The first operation for appendiceal intussusception was reported in 1890, in a 13 month-old child. During the following years, Wright, Renshaws, Pitts and Mc Graw presented different operations for this lesion [1].

Through a study that has been conduced over a period of 40 years and that included the examination of 71 000 of appendicular specimens taken from surgical and autopsy material, Collins reported prevalence of 0.01% for intussusception of the appendix [2].

The prevalence of endometriosis and adeno-carcinoma of the appendix were 0.05% and 0.08% respectively [1].

Intussusception of the appendix may occur at any age [7].

The majority of the reported studies included children and very young patients, with the average of 16 years [4].

The condition is more common four to five times in males than in females [1, 2].

Clinical manifestation is characterized through vague abdominal pain, recurrent and intermittent

rectoragies, mucus and blood in stool [1].

Casteels M *et al.* describe five possible clinical features: (1) acute appendicitis; (2) intussusception; (3) recurrent right iliac fossa pain; (4) rectal bleeding; (5) asymptomatic findings – incidental discovery during laparotomy. Laboratory exams do not offer any useful information for a diagnosis [1].

Physiopathological features that determine the invagination of the appendix can be divided in two large groups: anatomic and pathologic [2].

Anatomical conditions are represented by: (1) fetal-type of cecum, with appendix originating from its tip; (2) a wide appendicular lumen with the proximal lumen of greater diameter than its distal part; (3) a mesoappendix that is thin, free from fat and with a narrow base; (4) a mobile appendicular wall capable of active peristaltism; (5) an appendix that is free, unfixed by peritoneal folds or adhesions [1, 2].

Pathological conditions responsible for this entity are the abnormal appendicular peristaltism, the irritation of appendix caused by fecaliths, foreign bodies, neoplasms (polyps, mucinous cystadenoma, adeno-carcinoma, carcinoid tumor), parasites, endometrial implants and lymphoid follicles [5, 8–10].

Intussusception of the appendix may occur in an appendix even without an underlying abnormality [1, 2], such as observed in the case presented.

In 1941, McSwain modified the original classification for intussusception of the appendix presented by Moschcowitz [1, 2]: *type 1*, affects only the tip of appendix which is intusssuscepted into its proximal portion; *type 2*, middle part of the appendix intussuscepted into its proximal part; *type 3*, the base of the appendix intussuscepted into the cecum; *type 4*, the proximal portion of the appendix forms the intussusceptum and is received into the distal part; *type 5*, the complete inversion of the appendix intussuscepted into the cecum, with or without ileocecal or cecocecal intussusception (Figure 6).

Inverted appendiceal stump is another condition, a rare complication of appendectomy, and these are found at the appendiceal orifice in patients who have undergone appendectomy with inversion of the stump, usually when a purse-string suture is utilized [11, 12].

Symptoms associated with this entity were abdominal pain (95%), vomiting (47%), blood per rectum (26%) and a palpable abdominal mass (68%) [13].

The stump can be mistaken like a polyp and excised.

Although La Salle AJ *et al.* affirm that the onset of symptoms occurred within the first two weeks following appendectomy in 84% of cases [13], in our case the first clinical symptoms were obvious at about 24 years from the appendectomy.

Cases of appendicular invagination were diagnosed during barium enema, sometimes at asymptomatic patients. Levin *et al.* describe 11 cases with characteristic radiological signs, like coiled-spring in cecum or nonfilling of the appendix. Radiological abnormalities include: (1) no abnormality seen in cecal region, absence of appendix; (2) oval or round bosselated intraluminal filling defects, usually in the medial wall of the cecum, with no visualization of the appendix; (3) intraluminal finger-like filling defects within the cecum, usualy arising from the medial wall of the cecum; (4) reduction of the filling defect out of the cecum during fluoroscopy (Table 1) [1, 14, 15].

Table 1 – *Characteristic findings of intussuscepted appendix* [2]

Ultrasound sonography
▪ Target-like appearance
▪ Multiple concentric ring sign
Barium enema
▪ Coiled-spring sign
▪ Cecal filling defect with non-filling of the appendix
Computed tomography
▪ Well-demarcated cylindrical mass of soft tissue density
Colonoscopy
▪ Mushroom-like polypoid tumor with a dimple at the top
▪ Foreskin and glans appearance

During colonoscopy the invagination of the appendix can be mistaken for a polyp or a neoplasm [1, 4], and represents an important diagnosis of which the endoscopist must be aware and must relate to, especially when the appendiceal orifice can not be identified [9, 16, 17].

Endoscopic removal of this lesion is associated with a high risk of peritonitis [1, 9].

Fazio RA *et al.* describe the resection of an inverted appendix during colonoscopy. Eighteen hours after the procedure, local peritonitis was discovered, which was heralded by acute right lower quadrant pain [18].

The majority of patients suffer a laparoscopic examination followed by an appendectomy, cecotomy or even a hemicolectomy, because it has been noticed that in 52–63% of the cases of appendicular invagination in adults appear due to a tumor [9].

Although Levine MS, Bachman AL and Clemett AR suggest that appendiceal intussusception can be a transient phenomenon, rare cases of spontaneous reduction in adults were also reported [2].

Through the large majority of cases presented in the literature were diagnosed by radiological, sonographic or colonoscopic examination, in our case, histopathological diagnosis had a deciding part, identifying the histological structure of an inverted appendix.

The evolution of the patient was favorable, without presenting any complications.

References

[1] Ryu B. Y., Kim T. H., Jeon J. Y. *et al.*, *Colonoscopic diagnosis of appendiceal intussusception: a case report*, J Korean Med Sci, 2005, 20:680–682.

[2] Komine N., Yasunaga C., Nakamoto M. *et al. Intussusception of the appendix that reduced spontaneously during follow-up in a patient on hemodialysis therapy*, Internal Med, 2004, 6:479–483.

[3] Jevon G. P., Daya D., Qizilbash A. H., *Intussusception of the appendix: a report of four cases and review of the literature*, Arch Pathol Lab Med, 1992, 116:960–964.

[4] Ram A. D., Peckham C., Akobeng A. K. *et al.*, *Inverted appendix mistaken for a polyp during colonoscopy and leading to intussusception*, J Cyst Fibros, 2005, 4:203–204.

[5] Duncan J. E., DeNobile J. W., Sweency W. B., *Colonoscopic diagnosis of appendiceal intussusception: case report and review of the literature*, JSLS, 2005, 9:488–490.

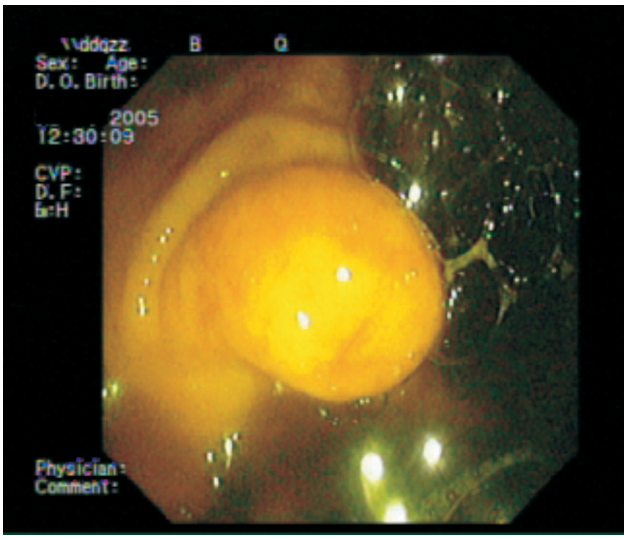

Figure 1 – ***A polypoid mass in the cecum. Colonoscopic image***

Figure 2 – ***The cecal polyp after endoscopic removal***

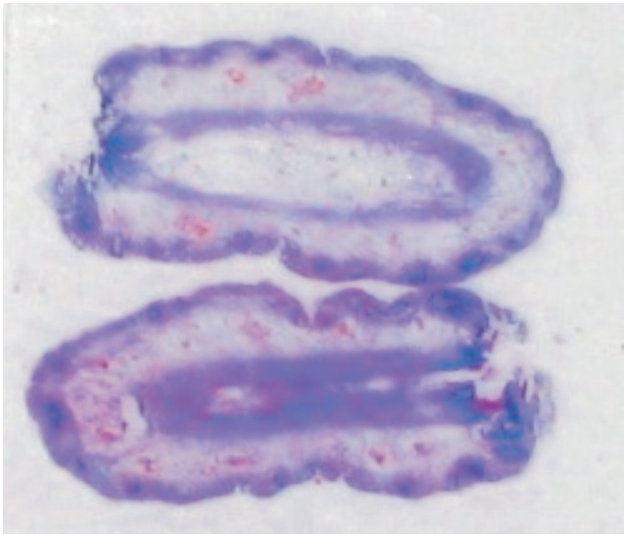

Figure 3 – ***Polyp with inverted structure of the appendix (HE stain, ×40)***

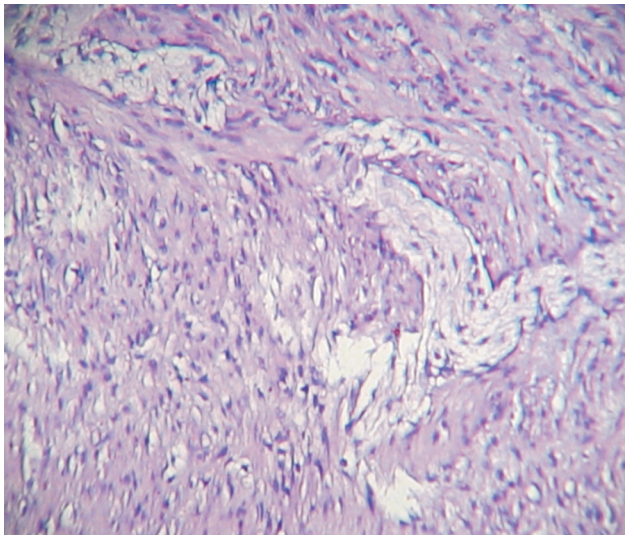

Figure 4 – ***The myenteric plexus between muscular layers (HE stain, ×100)***

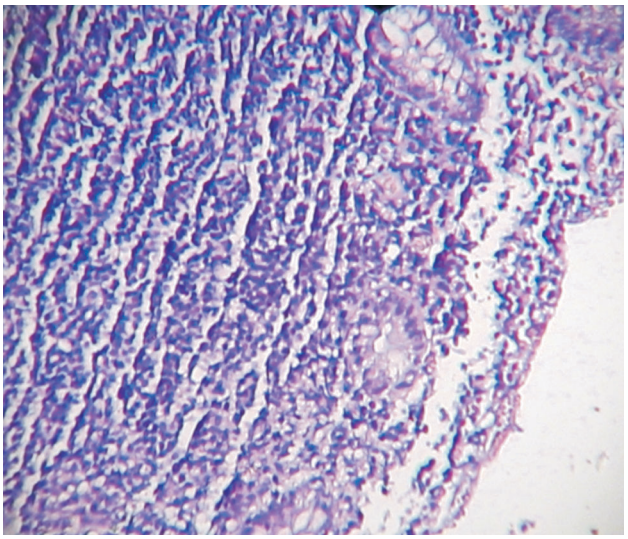

Figure 5 – ***Appendiceal type mucosa with prominent lymphoid tissue (HE stain, ×100)***

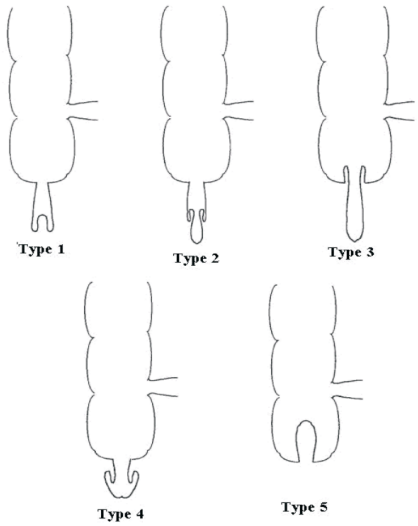

Figure 6 – ***Classification of appendiceal intussusception proposed by McSwain*** **[1, 2]**

[6] CASTEELS M., EGGERMONT E., KERREMANS R. *et al.*, *Intussusception of the vermiform appendix: A preoperative diagnosis in an adolescent girl*, J Pediatr Gastroenterol Nutr, 1986, 5:159–162.
[7] MATHEW J., ALDEAN I. M., GHAFAR F. A. *et al. Appendicular intussusception into a polyp*, Tech Coloproctol, 2004, 8:113–115.
[8] RUDEK B., VON HERBAY A., SCHMIDT J., *Intussusception of the appendix secondary to mucinous cystadenoma*, Dig Surg, 2001, 18(5):422–426.
[9] TAKAHASHI M., SAWADA T., FUKUDA T., KUWANO H., *Complete appendiceal intussusception induced by primary appendiceal adenocarcinoma in tubular adenoma: a case report*, Jpn J Clin Oncol, 2003, 33(8):413–415.
[10] SAKAGUCHI N., ITO M., SANO K. *et al.*, *Intussusception of the appendix: a report of three cases with different clinical and pathological features*, Pathol Int, 1995, 45:757–761.
[11] THOMAS S. E., DENNING D. A., CUMMINGS M. H., *Delayed pathology of the appendiceal stump: a case report of stump appendicitis and review*, Am Surg, 1994, 60(11):842–844.
[12] FENOGLIO-PREISER C., Intussusception, autoamputation and inverted appendiceal stump. In: *Gastrointestinal Pathology. An atlas and text*, 2nd edition, Lippincott–Raven, 1999, Chapter 12:520.
[13] LA SALLE A. J., ANDRASSY R. J., PAGE C. P. *et al.*, *Intussusception of the appendiceal stump*, Clin Pediatr, 1980, 19(6):432–435.
[14] LEVINE M. S., TRENKNER S. W., HERLINGER H. *et al.*, *Coiled-Spring sign of appendiceal intussusception*, Radiol, 1985, 155:41–44.
[15] BACHMAN A. L., CLEMETT A. R., *Roentgen aspects of primary appendiceal intussusception*, Radiol, 1971, 101:531–538.
[16] OZUNER G., DAVIDSON P., CHURCH J., *Intussusception of the vermiform appendix: preoperative colonoscopic diagnosis of two cases and review of the literature*, Int J Colorect Dis, 2000, 15:185–187.
[17] JARVENSIVU P., LEHTOLA J., KARVONEN A. L. *et al.*, *Colonoscopic appearance of the remnant of the appendix after total inversion*, Endoscopy, 1982, 14(2):66–68.
[18] FAZIO R. A., WICKREMESINGHE P. C., ARSURA E. L. *et al.*, *Endoscopic removal of an intussuscepted appendix mimicking a polyp – an endoscopic hazard*, Am J Gastroenterol, 1982, 8:556–558.

Mailing address
Sorina Tăban, Assistant Professor, MD, PhD, Department of Pathology, "Victor Babeş" University of Medicine and Pharmacy, 2 Eftimie Murgu Square, 300 041 Timişoara, Romania; Phone: +40748–331 269, +40256–204 476, E-mail: sorinataban@yahoo.com

Received: July 12th, 2006

Accepted: September 15th, 2006