ORIGINAL PAPER

# Diagnostic and differential diagnostic criteria of lymphoid neoplasms in bone marrow trephine biopsies: a study of 87 cases

EMŐKE HORVÁTH[1)], T. MEZEI[1)], Z. PÁVAI[2)], M. TURCU[1)], SMARANDA DEMIAN[3)], ERIKA TÓTH[4)], LILIANA CHIRA[1)], I. JUNG[1)]

[1)] *Department of Pathology*
[2)] *Department of Anatomy and Embryology*
[3)] *Clinics of Internal Medicine I*
*University of Medicine and Pharmacy of Targu Mures, Romania*
[4)] *National Institute of Oncology, Budapest, Hungary*

**Abstract**

The aim of this study is to present the diagnostic and differential diagnostic criteria of the bone marrow specimen involved by lymphomas based on the histomorphological immunophenotype features and clonality of the tumor cells, patterns of lymphoproliferation and diagnostic pitfalls. BMB material obtained from the right posterior iliac crest was represented from 87 untreated and treated patients with BM involving malignant lymphoma, stained with Hematoxylin–Eosin, Giemsa, Periodic Acid Schiff and Gömöri's Silver. In order to perform immunohistochemistry examination we used a large antibody panel. B-cell clonality was determined in six cases. We found eight reactive lymphoproliferative responses and 79 lymphoid neoplasms of which 45 were diagnosed as *de novo* lymphoma, the rest of 34 samples being examined for staging. The predominant lymphoma was CLL (30 cases), over followed by DLBCL (18 cases). The most frequent patterns of involvement were the interstitial (29%) and mixed (15%) ones. In eight cases, we found reactive lymphoid aggregates. The B-cell clonality test showed four monoclonal, one oligoclonal and one polyclonal diseases form. Diagnosis of lymphoma *versus* reactive aggregate has been based on the combination of a lot of antibodies and involvement pattern. Although investigation of gene rearrangement was necessary for the establishment of the correct diagnosis in only 6.9% of cases, it should be emphasized that it is of great importance in disease monitoring.

***Keywords***: bone marrow trephine biopsy, pattern of involvement, immunohistochemistry, polymerase chain reaction clonality test.

## Introduction

Examination of the bone marrow (BM) represents a central importance for the diagnosis and staging of lymphomas. Indications for a bone marrow trephine biopsy (BMTB) include all disorders in which the aspirated material may not be representative of the quantitative relationship of the cellular elements, myelosclerosis (no material may be obtainable, dry tap), assessment of cellularity in focal disease, and diagnosis of hypoplastic state.

The diagnosis of lymphoma from BMTB is of particular clinical interest, as therapy becomes increasingly stratified. Above all, bone marrow biopsy (BMB) may represent the least invasive method and the only source for lymphoma identification in many clinical settings. Diagnosis of malignant lymphoma is established incidentally by a routine BMTB in some patients.

The differential diagnosis of the lymphoid infiltrates in BM is more problematic than the disease typing. Although most lymphoid infiltrates can be considered as either reactive or neoplastic based on the extent of involvement, distribution, cytological finding and immunophenotype, a minority of cases cannot be classified with certainty, in spite of using a large immunohistochemical panel. In these cases, clonality determination of lymphoproliferative disorders is indispensable.

## Material and Methods

Quantitatively sufficient, formalin-fixed BMB material obtained from the right posterior iliac crest was represented from 87 untreated and treated patients, who were diagnosed with lymphoma between November 1st 2006 to October 1st 2008.

BMB specimens were examined in order to establish the positive diagnosis or to stage the lymphoma.

Tissue samples were fixed in 10% buffered formalin, decalcified in EDTA, embedded in paraffin and cut at 4–5 μm for Hematoxylin–Eosin staining (as routine histology), Giemsa, Periodic Acid Schiff (used for specific components) and immunohistochemical examination. The overview of source and clone, the pretreatment conditions and the dilution of the antibodies used in our study (for positive and differential diagnosis), were summarized in Table 1.

Specificities included: (1) lineage restricted antigens identifying lymphoid cells, (2) markers indicating cell

differentiation stages, (3) markers of clonality, and (4) markers normally not detected in bone marrow tissue (for example, CD23, CD30, cyclin-D1).

The antigen expression was visualized using the UltraVision LP Large Volume Detection System HRP Polymer and DAKO EnVision™/HRP kit, followed by Hematoxylin-counterstaining. As positive control, we used the primary tumor in cases examined for lymphoma staging and normal lymph node or tonsilla for cases examined for diagnostic purpose. The primary antibody was replaced by normal mouse or rabbit serum in negative control reactions. Our diagnosis was based on the pattern of BM infiltration (reported in Table 2) and tumor cells morphology, immunophenotype and molecular analysis according to the 2001 *World Health Organization (WHO) Classification of lymphoid tumors* [1]. For a comparison of the features which may help to discriminate between benign lymphoid aggregates in bone marrow and neoplastic involvement we used the morphological criteria recommended by Thiele J *et al.*, 1999 [2].

**Table 1 – *List of antibodies and their applicability conditions***

| Marker | Dilution | Staining in tumor cells | Specificity | Antigen retrieval methods |
|---|---|---|---|---|
| | | ***B-lymphocytes*** | | |
| *CD20cy (DAKO clone L26)* | 1/200 | Membrane staining | pan B | HIER/CITRATE, pH 6 |
| *CD138 (DAKO clone MI15)* | 1/50 | Membrane staining | Subset of B-cell | HIER/CITRATE, PH 6 |
| *CD79a (DAKO clone JCB117)* | 1/50 | Membrane staining | pan B | HIER/CITRATE, pH 6 |
| *CD10 (NOVOCASTRA, clone 56C6)* | 1/75 | Membrane staining | B-lymphoblasts germinal center cells | HIER/CITRATE, pH 6 |
| *CD23 (DAKO clone MHM6)* | 1/40 | Membrane staining | Subset of B-cells (CLL) | HIER/CITRATE, pH 6 |
| *cyclinD1 (Lab Vision, Clone SP4)* | 1/50 | Nuclear staining | Mantle cell lymphoma | HIER/CITRATE, pH 6 |
| | | ***T-lymphocytes*** | | |
| *CD3* | 1/60 | Membrane staining | Pan T | HIER/EDTA |
| *CD4 (NOVOCASTRA, clone 4B12)* | 1/40 | Membrane staining | Helper cells | HIER/CITRATE, pH 9 |
| *CD8 (NOVOCASTRA 1A5)* | 1/40 | Membrane staining | Supressor cells | HIER/CITRATE, pH 9 |
| *CD5* | 1/200 | Membrane staining | T-cells, B-cell subset | HIER/CITRATE, pH 6 |
| | | ***Plasma cells*** | | |
| *Kappa light chain* | 1/250 | Cytoplasmic staining | Clonality examination | HIER/CITRATE, pH 6 |
| *Lambda light chain (LabVision, clone N/10/2)* | 1/25 | Cytoplasmic staining | Clonality examination | HIER/CITRATE, pH 6 |
| *Ig G (LabVision, polyclona)Rb1432)* | 1/1000 | Cytoplasmic staining | Clonality examination | HIER/CITRATE, pH 6 |
| *IgA (LabVision, polyclonal Ab-1)* | 1/100 | Cytoplasmic staining | Clonality examination | HIER/CITRATE, pH 6 |
| *IgM (LabVision, polyclonal R1/69)* | 1/40 | Cytoplasmic staining | Clonality examination | HIER/CITRATE, pH 6 |
| *CD38 (LabVision, clone 38CO3)* | 1/100 | Cytoplasmic staining | Prognostic marker in CLL | HIER/CITRATE, pH 6 |
| *CD138 (DAKO clone MI15)* | 1/50 | Membrane staining | May be positive in epithelial cells | HIER/CITRATE, pH 6 |
| | | ***Proliferation/Cell cycle markers/Other*** | | |
| *CD30 (LabVision, Clone BerH2)* | 1/80 | Membrane staining | R-S cells, T-cells subset | HIER/EDTA |
| *CD21 (Lab Vision clone 2G9)* | 1/20 | Membrane staining | Follicular dendritic cells | HIER/CITRATE, pH 6 |
| *ALK (Lab Vision p80)* | 1/100 | Cytoplasmic | T-tumor cell, B-tumor cell subset | HIER/CITRATE, pH 6 |
| *MUM1 (DAKO clone MUM1p)* | 1/50 | Nuclear staining | B-tumor cell subset | HIER/CITRATE, pH 6 |
| *CD34 (Lab Vision clone BI-3C5)* | 1/100 | Cytoplasmic staining | Endothelial cells | HIER/CITRATE, pH 6 |
| *Ki67 (LabVision, clone SP6)* | 1/200 | Nuclear staining | Ki67-index | HIER/CITRATE, pH 9 |

**Table 2 – *Pattern of lymphoproliferation in the bone marrow depending on the histological subtype***

| Pattern of lymphoproliferation in the BM | CLL | DLBCL | MZL | HCL | FL | LPL | PTCL | ALCL | HL | No. of cases |
|---|---|---|---|---|---|---|---|---|---|---|
| *Interstitial (36.7%)* | 10 | 9 | 4 | 4 | – | – | 2 | – | – | 29 |
| *Nodular (12.65%)* | 4 | 2 | 4 | – | – | – | – | – | – | 10 |
| *Paratrabecular (7.5%)* | – | – | – | – | 3 | 2 | 1 | – | – | 6 |
| *Sinusoidal (10.12%)* | – | – | 8 | – | – | – | – | – | – | 8 |
| *Single (1.2%)* | – | – | – | – | – | – | 1 | 1 | – | 1 |
| *Diffuse (12.65%)* | 4 | 4 | – | 1 | – | – | – | – | 1 | 10 |
| *Mixed (18.98%)* | 12 | 3 | – | – | – | – | – | – | – | 15 |
| ***Total*** | 30 | 18 | 16 | 5 | 3 | 1 | 3 | 1 | 1 | 79 |

A fibrotic response caused by lymphoma involvement was visualized by Gömöri's Silver and van Gieson stains, and graded semi-quantitatively in grades 1–4.

B-cell clonality was determined in minority of cases (two cases with diffuse large B-cell lymphoma-DLBCL-, two cases with follicular lymphoma-FL-, one case with chronic lymphocytic leukemia-CLL-, and one case with lympho-plasmocytic lymphoma-LPL-), which cannot be classified with certainty based on

extent of involvement, distribution and immunophenotype in order to determine disease stage

For the assessment of B-cell clonality we used a previously published protocol [3] and optimized primers developed in the BIOMED-2 study [4, 5].

DNA obtained from paraffin-embedded bone marrow sections was purified using a commercially available extraction kit (Fermentas Genomic Purification Kit). The purification protocol includes overnight digestion with proteinase K. For immunoglobulin heavy chain gene rearrangement tests a simple pair of primers was used with the forward primer directed at the VH region (framework region 3/FR3) and the reverse primer at the JH consensus region. We performed real time PCR using a Roche Lightcycler 2 instrument. The thermal cycler program was the following: 40 cycles of PCR of 30 seconds at $94^0$C, 30 seconds at $60^0$C, and 30 seconds at $72^0$C were performed after preheating to $95^0$C, 10 minutes. The final extension time was 5 minutes at $72^0$C. As controls, we used DNA samples extracted from a B-cell lymphoma (monoclonality), a normal lymph node (for polyclonality) and a reaction without template DNA (negative control). The amplified products were analyzed with microcapillar electrophoresis on an Agilent Bioanalyzer 2100 instrument. The results were represented by fluorescence plot and by simulated electropherogramm.

For the final diagnosis all the collected results have to be integrated (clinical information: suspected clinical diagnosis, peripheral blood cell count, lymph node enlargement yes/no if yes, size and sites, size of liver and spleen; bone marrow aspiration: morphology cytology, previous biopsies: histology/immunophenotyping, clonality and paraclinical investigations).

## Results

In the period of November 1st 2006 to October 1st 2008, 87 BMBs were obtained that presented lymphoproliferation in the BM. We found eight reactive lymphoproliferative responses and 79 lymphoid neoplasms, of which 45 were diagnosed as *de novo* lymphoma, the rest of 34 samples being used for staging (Table 3).

**Table 3 – *Aim of histological investigation and subtyping of lymphomas in our study***

| Lymphoma type | Diagnose | Staging | Total |
|---|---|---|---|
| *CLL* | 21 | 9 | 30 |
| *SMZL* | 12 | 4 | 16 |
| *DLBCL* | 4 | 14 | 18 |
| *HCL* | 5 | 0 | 5 |
| *FL* | 0 | 3 | 3 |
| *LPL* | 2 | 0 | 2 |
| *PTCL* | 1 | 2 | 3 |
| *ALCL* | 0 | 1 | 1 |
| *HL–NS* | 0 | 1 | 1 |
| ***Total*** | 45 | 34 | 79 |

Fifty-seven patients presented with nodal disease, 22 patients with extranodal sites. The most common extranodal sites was the gastrointestinal tract (six cases), characteristic for DLBCL, and the spleen (16 cases), typical for splenic marginal zone lymphoma (SMZL) with nodular and sinusoidal pattern of involvement in the bone marrow (Figure 1).

### Clinical data

Age range in the lymphoma patient's group was from 17 to 86 years, with an average of 60.70± 1.65 years. Regarding distribution of genders, 46 males and 33 females composed the group.

All the patients with a diagnosis of CLL have involvement of bone marrow and peripheral blood at the time of the diagnosis and a lymphocyte count $>10\times10^9$/L.

### Histopathology and immunohistochemistry

The diagnostic algorithm is based on the morphological aspects examined by low power.

In a good quality marrow section, stained parallel by the HE and Giemsa method, most of the normally differentiated cell types can be identified. The lymphoproliferation in BM has been visualized by PAS stain. We examined the reticulin fiber network in the stroma by Gömöri Silver's and van Gieson stains. Fibrosis caused by lymphoma was focal (four cases, grade 2) or generalized (five cases, grade 3). We found fibrosis associated with lymphoma in Hairy-cell leukemia (HCL) (Figure 2), DLBCL, and nodular sclerosis Hodgkin lymphoma (HL–NS). Reticular fibrosis grades 1–3 are non-specific, but fibrosis assessment is important since indicates an abnormal bone marrow.

By type, 73 cases were B-cell lymphomas, as all expressed B-cell phenotype immunohistochemically, and only five cases were of T-cell origin (four cases) or HL–NS (one case) (Figure 3).

The predominant lymphoma was CLL (30 cases) (Figure 4), of which four showed CD38 and p53-expression (appear to have a worse prognosis), over followed by DLBCL (18 cases). In our study, we found in 15 BM specimens DLBCL tumor cells with similar morphologic variants such as in nodal or extranodal site (Figure 5). The most common extranodal sites were the gastrointestinal tract (six cases). In three cases, the tumor infiltration presented a discordant bone marrow involvement mimicking a low-grade B-cell lymphoma in the BM. In these cases the high proliferation index (Ki67-positive cells >40%) helped us in resolving the diagnostic dilemma.

We presented the pattern types of lymphoproliferation in the bone marrow depending on the histological subtype in Table 2. The most frequent patterns of involvement were the interstitial (29%) and mixed (15%) ones.

In eight cases, we found reactive lymphoid aggregates in the BM tissue examined in order to diagnosis. It was characteristic for aged people (mean age 65.63±1.354 years), with systemic autoimmune disease (three cases), or other neoplastic process (one case treatment induced myelodysplastic syndromes), HBV-infection (two cases), but appeared also in two conditions of unknown origin.

## Molecular findings

### *B-cell clonality results*

After the assessment of the six problematic cases, we found the followings: four proved to be monoclonal (Figures 6 and 7), one oligoclonal and one polyclonal. The first four cases showed clear-cut monoclonality meaning that the vast majority of the cells emerged from the same malignant clone.

The oligoclonal case (Figure 8) was earlier diagnosed as CLL but a few months later transformation into a DLBCL occurred. The case that showed polyclonality after revision was classified as reactive lesion of the bone marrow.

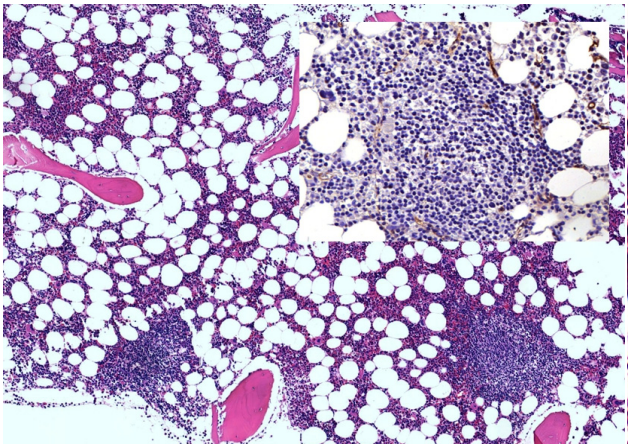

**Figure 1** – ***BM involvement in SMZL with two large lymphoid aggregates. Inset: Low magnification showing that the infiltrate is intrasinusoidal too (visualized by stain for CD34).***

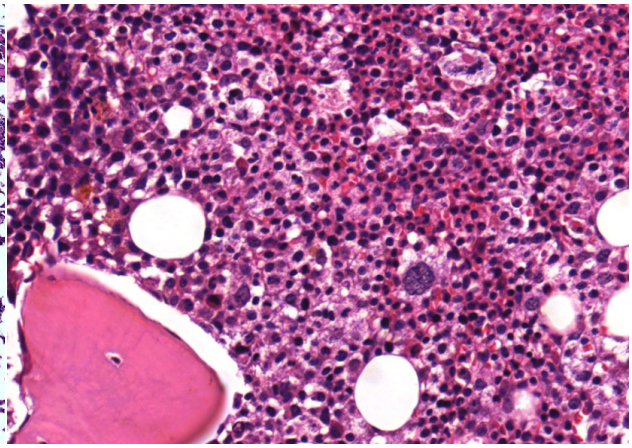

**Figure 3** – ***"Packed marrow" with the presence of the Reed-Sternberg cells, surrounded by reactive elements.***

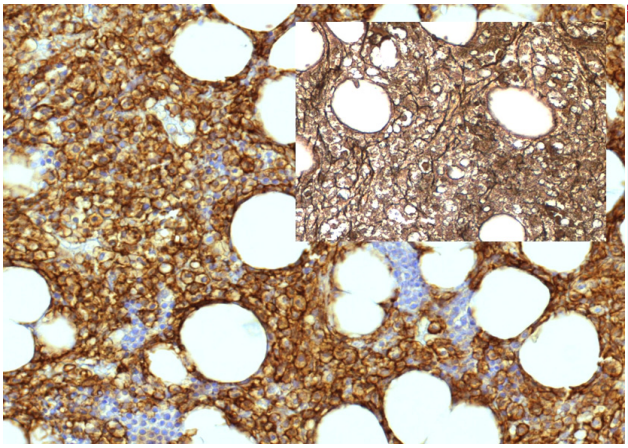

**Figure 2** – ***HCL characterized by interstitial infiltration of CD20-positive tumor cells. Inset: reticular fibrosis grade 3, stained by Gömöri's silver stain.***

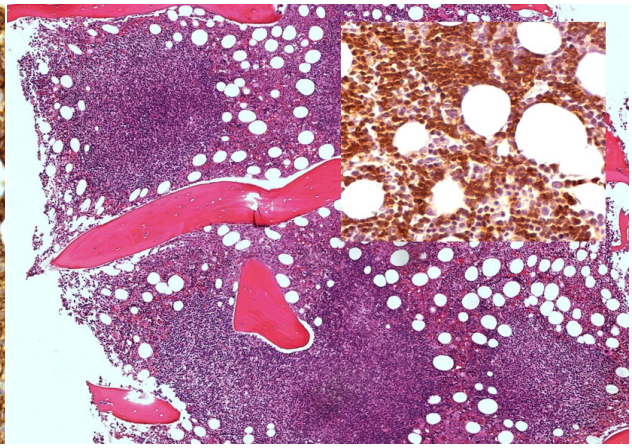

**Figure 4** – ***CLL: Nodular and interstitial pattern of involvement (HE stain). Inset: Tumor cells express CD79a.***

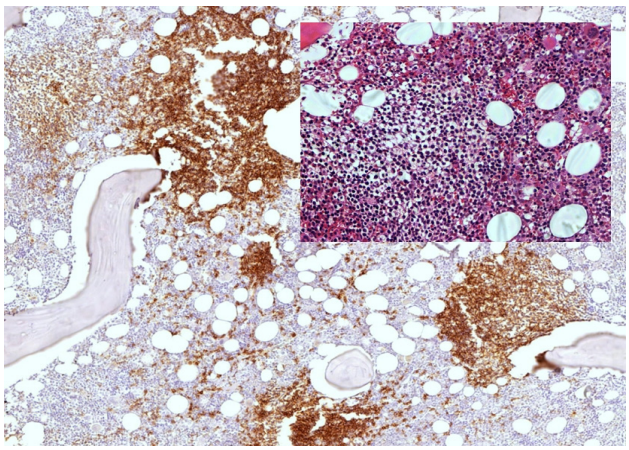

**Figure 5** – ***DLBCL: Nodular and paratrabecular pattern of infiltration visualized by CD20. Inset: large tumor cells with monomorphic appearance (centroblastic variant, HE stain).***

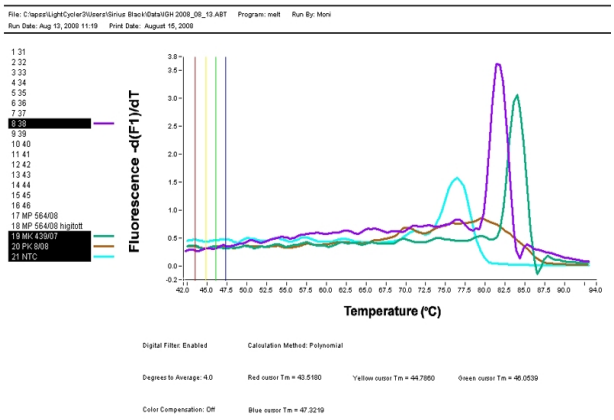


**Figure 6** – ***Aspect of monoclonality with lightcycler analysis.***

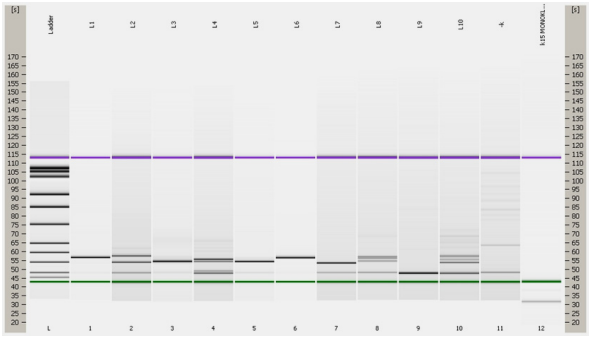

**Figure 7** – ***Simulated electropherogramm.***

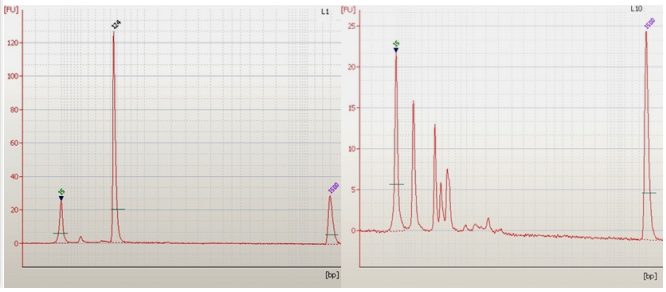

**Figure 8**– ***Aspect of monoclonality and oligoclonality represented by fluorescence plot.***

## Discussion

The type of fixative and the fixation time used for BM biopsies influence the immunoreactivity and determine the success of the ancillary molecular biology techniques. Conventional formalin-fixed, EDTA-decalcified, paraffin-embedded BM tissues are suitable for all methods (morphology, immunohistochemistry, FISH, PCR, etc.) in order to establish the final diagnosis. In our experience, fixation in buffered neutral formalin for 24 hours followed by EDTA decalcification preserves the morphological details and their antigen spectrum.

The most frequent B-cell lymphoma (30 cases) was represented by CLL, because the flow cytometry examination was not attainable for all intermediate grade lymphoma cases. In BM biopsy sections, the pattern of infiltration is nodular in approximately 7% of the cases, interstitial in 34%, mixed in 24%, diffuse in 35%. A diffuse BM infiltration pattern probably predicts a worse prognosis [7]. In our study we found a predominantly mixed pattern of infiltration (40%/ 12 cases) *versus* interstitial infiltration pattern (33.33%/10 cases). This pattern is typical in CLL, where occasional large transformed cells may be admixed with the small lymphocytes, but lymphoplasmocytic lymphoma (LPL), HCL, SMZL and peripheral T-cell lymphoma (PTCL) may have interstitial pattern of BM-involvement.

The nodular form represents 13.33% (four cases) in our study. Differential diagnosis between low-grade lymphomas showing follicular colonization (mantle cell lymphoma, SMZL, CLL) and benign lymphoproliferative infiltration is important. In rare cases, DLBCL has nodular aspect.

The mixed infiltration refers to a combination of nodular and interstitial infiltration, in the pathologic report we described the two patterns and indicated the prevalent one.

The diffuse infiltration that we found in four cases (13.33%), which replaced totally the hematopoietic and fat cells, defines massive infiltration. This pattern predicts a worse prognosis.

In CLL, the neoplastic lymphocytes always express pan-B markers, although CD20 expression is of lower intensity as compared to other B-chronic lymphoproliferative diseases [8]. The usual immunohistochemical panel (CD79a, CD5, and CD23) was completed with the determination of CD38 and p53 expression in diffuse infiltration pattern – as independent prognostic factors [9, 10] – positivity being found in all four cases.

DLBCL is the most frequent non-Hodgkin lymphoma, usually involves in rare cases the BM-tissue. In literature, BM-involvement is reported in 11–27% of cases [11]. The prognostic significance of marrow involvement in diffuse large cell lymphoma (DLBCL) is controversial. Factors that have been reported to influence prognosis include the pattern and extent of marrow infiltration and histological discordance between the primary site and the BM [12]. DLBCL has a variable pattern, characterized by paratrabecular, nodular, sinusoidal or diffuse infiltration. In our study, we found in 15 BM specimens tumor cells with similar morphologic variants such as in nodal or extranodal site. The tumor cells immunophenotype changes depending on the DLBCL variants, subgroups and subtypes [13].

Diagnostic criteria of SMZL initially relied on the histopathological features of the spleen. However, in cases with clinical splenomegaly, or in cases where histological material from the spleen is not available, a reliable diagnosis can be established from a combined study including the morphological and immunophenotypical profile of the peripheral blood lymphocytes and bone marrow involvement. Recently proposed minimum diagnostic criteria also include: spleen histology and immunophenotypical expression with a CLL score 2 or less, or typical blood and BM-morphology accompanied by $CD20^{+}$ lymphocytes with intrasinusoidal pattern of infiltration [14]. In our 12 cases without splenectomy, the diagnosis was based on blood and BM-morphology, clinical and immunohistochemical findings. The most frequent pattern of infiltration was the intrasinusoidal pattern (50%), followed by nodular and interstitial pattern (25–25%). CD34/CD20 immunostaining is decisive for highlighting this pattern of infiltration. An intrasinusoidal type may be prominent in SMZL, but not always present. Subtle infiltration may be seen in the initial phase of the disease. Intrasinusoidal infiltration is characteristic of SMZL, but not pathognomonic as it may be observed in other small B-cell lymphoproliferative disorders. After splenectomy the bone marrow pattern of infiltration may become nodular [15].

All the HCL cases were examined in order to establish a positive diagnosis. An increase in appearance

of reticulin fibers is associated with all hairy cell infiltrates in BM and other sites and often results in a "dry-tap" [16]. The involvement of BM by tumor cells is variable, in early stage is interstitial/focal, in advanced disease we found a diffuse solid infiltrate. In absence of the CD103 and FMC7 antibody, the positive diagnosis is based on the classical morphologic criteria [17] that have been completed by Gömöri's Silver stain and immunophenotyping/cytochemistry techniques and peripheral blood smear's examination.

In our three cases of follicular lymphoma (FL) and in two cases of LPL we found a paratrabecular pattern. The infiltrate lines the bone trabeculae either in a band-like fashion immediately adjacent to the trabecula or as an aggregate with a broad base connected with the trabecula. The immunonophenotype of the tumor cells was similar with the lymph node involvement.

The BM-involvement by three FL cases was characterized by paratrabecular aggregates composed of centrocytes expressing FL-specific antigens (CD10, bcl-2, bcl-6). The most important factor is the distinction from the reactive lymphoid aggregates.

Evaluation of bcl-2 expression gives an aid only in differentiating between lymphoma and a reactive process, because most of the low-malignancy NHL's are identifiable CD10 expression often disappears in G3 cases.

The neoplastic cells were enmeshed in CD21 and CD23-positive FDCs, similarly to the basic structure of FL in lymph node. The presence of follicular dentritic cells (FDC) in the BM-infiltration suggests that FDCs are essential components of FL microenvironment, presumably because tumoral–non-tumoral cell interactions inhibit the apoptosis of the neoplastic B-cells and they provide the necessary antigenic stimuli for the survival of tumor cells [18].

We diagnosed one case of PTCL with paratrabecular infiltration in the BM-tissue, the tumor cells having the characteristic immunophenotype. Each of the two cases (examined for staging purposes) the interstitial pattern was similar to that primary site [19].

We diagnosed HL involved BM-tissue with total replacement of hematopoietic and fat cells as "packed marrow" with the presence of the Reed–Sternberg cells, surrounded by reactive elements. The BM appearance of mixed cellularity of nodular sclerosis is indistinguishable so that subtyping must be performed on lymph node biopsy. In most cases of nodal disease with spread to the marrow, diagnostic cells are rare but a combination of focal fibrosis and abnormal mononuclear cells with appropriate immunostaining will allow a confident diagnosis [20].

The incidence of BM by anaplastic large cell lymphoma (ALCL) has been estimated as approximately 10–15%, more frequent in the small cell subtype. The pattern of involvement may be nodular or diffuse, with many reactive lymphocytes and histiocytes that surround the low number of the CD30+ tumor cells [21].

Nevertheless, after immunohistochemistry was applied the percentage increased to 30–40% [15]. However, the characteristic CD30-positive expression in ALCL may be seen in BMB staged for ALCL in other types of lymphoma: Hodgkin's DLBCL, ALBCL. In these cases, the differential diagnosis has been based on the histological aspect the tumor tissue.

Underlying disorders with benign lymphocyte accumulation in bone marrow (eight cases) present similar percent with literature data is represented predominantly by autoimmune disorders [2].

In various publications, guidelines have been given in support of neoplasia: paratrabecular localization, size of nodule >1 mm, imprecisely defined borders, light chain restriction, B-cell count > T-cell count, clonal IgH rearrangements. Histotopography of reactive modifications is represented by rounded aggregates with germinal centers only 5% of cases, in 40% by aggregates with partial GC present, 40% by aggregates with fairly defined margin and 15% by the focal/nodular aggregates with interstitial spread (Indian file pattern) mimicking lymphoma infiltration pattern [22].

However, paratrabecular localization may be very limited, as it might occur in bone marrow involvement by MALT-lymphomas. Light chain restriction, which should always be considered, is not often identified by immunohistochemistry due to indiscernible cytoplasm.

## Determination of clonality in the diagnosis of lymphoproliferative disorders

Normal adult marrow contains an inconspicuous population of both B- and T-lymphocytes throughout the marrow. These lymphoid aggregates increase in number with age, being frequently seen in the elderly population and in different disorders [2]. Our five cases with benign lymphoid aggregates in BM did not present differential diagnosis problem, their characteristic features helped discriminate between reactive lymphoproliferation and neoplastic involvement.

The most important problem for the diagnosis of lymphoid neoplasm in BMB represents the differentiation between focal infiltrates of lymphoma and reactive nodular lymphoid hyperplasia. Although most lymphoid infiltrates can be diagnosed as either reactive or neoplastic based on extent of involvement, distribution, cytology and immunophenotype, a minority of cases cannot be classified with certainty. For some low-grade lymphoma entities, the detection of an aberrant immunophenotype may be difficult or impossible in small BM-infiltrates [23]. Identification of prominent monoclonal B-cell populations has been considered a marker of malignancy in lymphoid proliferation.

In order to increase the sensitivity for the detection of small clonal population in nodular lymphoid infiltrates (to stage) it is recommended to use microdissection to enrich the target cell population [24].

Clonality can be demonstrated in 50–90% of B–NHL cases, depending on the type of lymphoma and the method used for the analysis of amplification [25].

The result of PCR-analysis may be false negative or positive and with monoclonal or oligoclonal rearrangements which may be found particularly in small-sized tissue specimens. In such instances, the differential diagnosis between a reactive and neoplastic

lesion may be directly related to the pathologist's experience, the relevant clinical data and the laboratory's resources to allow PCR application according to recently established protocols [15].

## Conclusions

The assessment of the bone marrow biopsy is an integral part of a comprehensive bone marrow investigation including cytology on the aspirate and special studies depending on the clinical problem (flow cytometry, cytogenetics). For the final diagnosis, all the results collected must be integrated.

Basic requirements for bone marrow biopsy interpretation are the good biopsy processed by a high quality histological technique for optimal preservation of the morphologic details, be followed by adequate clinical information.

Even if the number of tumor cells is low in the marrow, biopsy is suitable for disease monitoring. Tumor cells preserve their original biological features, since the bone marrow, similar to the lymph node tissue, creates a favorable microenvironment.

The pattern of infiltration is useful in staging and evaluation of prognosis.

The molecular pathological analysis was very important in those six cases, when the diagnosis of the lymphoma *versus* reactive aggregate was partly based on PCR-analysis.

The diagnosis of the lymphoma *versus* reactive aggregate based on the combination many antibodies. In conjunction with immunohistochemistry, the determination of lymphoproliferation's clonality to paraffin-embedded BM trephines has significantly expanded the scope of histopathologic bone marrow examination.

In order to evaluation the Mabthera's therapeutically effect, the CD20-antibody solely is not proper for detection of the residual tumor cells, it is necessary to used CD79a, too.

After the survey of the results obtained from 87 patients, we can state that in 93.1% of cases morphology examination and immunophenotyping was sufficient for the positive diagnosis. Diagnostic difficulties were caused by a few technical and interpretational problems and the absence of some relevant antibodies. Although investigation of gene rearrangement was necessary for the establishment of the correct diagnosis in only 6.9% of cases, it should be emphasized that it is of great importance in disease monitoring.

**Acknowledgements**

This work was partially supported by Roche SRL Romania.

### References

[1] JAFFE S. E., HARRIS N., LEE N. L., STEIN H., VARDIMAN J. W., *Tumours of haematopoietic and lymphoid tissues*, World Health Organisation, IARC Press, Lyon, 2001, 119–255.

[2] THIELE J., ZIRBES T. K., KVASNICKA H. M., FISCHER R., *Focal lymphoid aggregates (nodules) in bone marrow biopsies: differentiation between benign hyperplasia and malignant lymphoma – a practical guideline*, J Clin Pathol, 1999, 52(4):294–300.

[3] KRENACS T., BAGDI E., STELKOVICS E., BERECZKI L., KRENACS L., *How we process trephine biopsy specimens: epoxy resin embedded marrow biopsies*, J Clin Pathol, 2005, 58(9):897–903.

[4] VAN DONGEN J. J. M., LANGERAK A. W., BRÜGGEMANN M., EVANS P. A. S., HUMMEL M., LAVENDER F. L., DELABESSE E., DAVI F., SCHUURING E., GARCÍA-SANZ R., VAN KRIEKEN J. H., DROESE J., GONZÁLEZ D., BASTARD C., WHITE H. E., SPAARGAREN M., GONZÁLEZ M., PARREIRA A., SMITH J. L., MORGAN G. J., KNEBA M., MACINTYRE E. A., *Design and standardization of PCR primers and protocols for detection of clonal immunoglobulin and T-cell receptor gene recombinations in suspect lymphoproliferations: report of the BIOMED–2 Concerted Action BMH4–CT98–3936*, Leukemia, 2003, 17(12):2257–2317.

[5] VAN KRIEKEN J. H. J. M., LANGERAK A. W., MACINTYRE E. A., KNEBA M., HODGES E., GARCIA SANZ R., MORGAN G. J., PARREIRA A., MOLINA T. J., CABEÇADAS J., GAULARD P., JASANI B., GARCIA J. F., OTT M., HANNSMANN M. L., BERGER F., HUMMEL M., DAVI F., BRÜGGEMANN M., LAVENDER F. L., SCHUURING E., EVANS P. A. S., WHITE H., SALLES G., GROENEN P. J. T. A., GAMEIRO P., POTT CH., VAN DONGEN J. J. M., *Improved reliability of lymphoma diagnostics via PCR-based clonality testing: report of the BIOMED–2 Concerted Action BHM4–CT98–3936*, Leukemia, 2007, 21(2):201–206.

[6] YAHALOM J., STRAUS D., Hodgkin Lymphoma. In: PAZDUR R., COIA L. R., HOSKINS W. J., WAGMAN L. D. (eds), *Cancer management: a multidisciplinary approach. Medical, surgical & radiation oncology*, Chapter 29, 10th edition, CMPMedica, 2007.

[7] PANGALIS G. A., VASSILAKOPOULOS T. P., KALPADAKIS C., ANGELOPOULOU M. K., PANAYIOTIDIS P., *B-chronic lymphocytic leukemia and small lymphocytic lymphoma*, Long Course, Update of the WHO Classification and new perspectives in lymphoid neoplasms, XXVIIth International Congress of the International Academy of Pathology, 2008, 5–12.

[8] PANGALIS G. A., VASSILAKOPOULOS T. P., DIMOPOULOU M. N., SIAKANTARIS M. P., KONTOPIDOU F. N., ANGELOPOULOU M. K., *B-chronic lymphocytic leukemia: practical aspects*, Hematol Oncol, 2002, 20(3):103–146.

[9] LIN K., SHERRINGTON P. D., DENNIS M., MATRAI Z., CAWLEY J. C., PETTITT A. R., *Relationship between p53 dysfunction, CD38 expression, and JgV(H) mutation in chronic lymphocytic leukemia*, Blood, 2002, 100(4):1404–1409.

[10] HAMBLIN T. J., ORCHARD J. A., IBBOTSON R. E., DAVIS Z., THOMAS P. W., STEVENSON F. K., OSCIER D. G., *CD38 expression and immunoglobulin variable region mutations are independent prognostic variables in chronic lymphocytic leukemia, but CD38 expression may vary during the course of the disease*, Blood, 2002, 99(3):1023–1029.

[11] CAMPBELL J., SEYMOUR J. F., MATTHEWS J., WOLF M., STONE J., JUNEJA S., *The prognostic impact of bone marrow involvement in patients with diffuse large cell lymphoma varies according to the degree of infiltration and presence of discordant marrow involvement*, Eur J Haematol, 2006, 76(6):473–480.

[12] SWERDLOW S. H., CAMPO E., HARRIS N. L., JAFFE E. S., PILERI S. A., STEIN H., THIELE J., VARDIMAN J. W., *WHO Classification of Tumours of Haematopoietic and Lymphoid Tissues*, IARC Press, Lyon, 2008.

[13] MATUTES E., OSCIER D., MONTALBAN C., BERGER F., CALLET-BAUCHU E., DOGAN A., FELMAN P., FRANCO V., IANNITTO E., MOLLEJO M., PAPADAKI T., REMSTEIN E. D., SALAR A., SOLÉ F., STAMATOPOULOS K., THIEBLEMONT C., TRAVERSE-GLEHEN A., WOTHERSPOON A., COIFFIER B., PIRIS M. A., *Splenic marginal zone lymphoma proposals for a revision of diagnostic, staging and therapeutic criteria*, Leukemia, 2008, 22(3):487–495.

[14] ANAGNOSTOU D., *Pitfalls in the pattern of bone marrow infiltration in lymphoproliferative disorders*, Curr Diagn Pathol, 2005, 11(3):170–179.

[15] BITTER M. A., Hairy cell leukemia and related disorders. In: KNOWLESS D. A. (ed), *Neoplastic Hematopathology*, 2nd edition, Lippincott Williams & Wilkins, Philadelphia, 2001, 1531–1555.

[16] JAFFE S. E., HARRIS N. LEE N. L., STEIN H., VARDIMAN J. W., *Tumours of haematopoietic and lymphoid tissues*, World Health Organisation, IARC Press, Lyon, 2001, 138–141.
[17] TÓTH E., SCHNEIDER T., MELEGH ZS., CSERNÁK E., UDVARHELYI N., ROSTA A., SZENTIRMAY Z., *Follicularis lymphomák komplex diagnosztikája*, Hungarian Oncology, 2005, 49(2):135–140.
[18] DOGAN A., MORICE W. G., *Bone morrow histopathology in peripheral T-cell lymphomas*, Br J Haematol, 2004, 127(2):140–154.
[19] FRANCO V., TRIPODO C., RIZZO A., STELLA M., FLORENA A. M., *Bone marrow biopsy in Hodgkin's lymphoma*, Eur J Haematol, 2004, 73(3):149–155.
[20] FALINI B., *Anaplastic large cell lymphoma: pathological, molecular and clinical features*, Br J Haematol, 2001, 114(4):741–760.
[21] SCHMID C., ISAACSON P. G., *Bone marrow trephine biopsy in lymphoproliferative disease*, Clin Pathol 1992, 45(9):745–750.
[22] FEND F., *Molecular diagnosis of lymphoid neoplasms in bone marrow trephine biopsies*, 7th International Course on Bone Marrow Biopsy Pathology, Krakow, 2005.
[23] KREMER M., CABRAS A. D., FEND F., SCHULZ S., SCHWARZ K., HOEFLER H., WERNER M., *PCR analysis of IgH-gene rearrangements in small lymphoid infiltrates microdissected from sections of paraffin-embedded bone marrow biopsy specimens*, Hum Pathol, 2000, 31(7):847–853.
[24] BRAUNSCHWEIG R., BAUR A. S., DELACRÉTAZ F., BRICOD C., BENHATTAR J., *Contribution of IgH–PCR to the evaluation of B-cell lymphoma involvement in paraffin-embedded bone marrow biopsy specimens*, Am J Clin Pathol, 2003, 119(5):634–642.

***Corresponding author***
Emőke Horváth, Lecturer, MD, PhD, Department of Pathology, University of Medicine and Pharmacy of Târgu Mureş, 50 Gheorghe Marinescu Street, 540000 Târgu Mureş, Romania; Phone +40265–212 111/250, Fax +40265–210 407, e-mail: horvath_emoke@yahoo.com

*Received: March 20th, 2009*

*Accepted: August 5th, 2009*