Rom J Morphol Embryol 2012, 53(1):95–98

ORIGINAL PAPER

RJME
Romanian Journal of Morphology & Embryology
http://www.rjme.ro/

Surgical management of the esogastric junction adenocarcinoma according to its histological types

D. ENE[1)], SMARANDA POPESCU[2)], RALUCA CIUREA[2)], CRISTINA DANIELA OPREA[3)], LORENA MIHAELA SFÎRLEAZĂ[4)]

[1)]*Clinic of General Surgery, "Floreasca" Emergency Hospital, Bucharest*
[2)]*Department of Morphology, University of Medicine and Pharmacy of Craiova*
[3)]*Medical Doctor, Private Practice, Craiova*
[4)]*Clinic of Radiology, Emergency County Hospital, Craiova*

Abstract

Most adenocarcinomas of the esophagus occur in the area of the cardia and originate in islands of gastrointestinal mucosa, less often in the submucosal glands, and are usually histologically similar to gastric adenocarcinoma and its various histological patterns. Most tumors are well differentiated. All patients included in this study were diagnosed with adenocarcinoma of the esogastric junction through prior endoscopy and histopathological examination of the biopsies. Patients with resectable tumors underwent surgical resection followed by histopathological examination of the resected samples. The most frequently encountered tumor was represented by type III, subcardial adenocarcinoma in 68% of all cases. The main surgical procedure was distal esophagectomy with total gastrectomy extended by abdominal transthoracic approach. All the studied cases were diagnosed with adenocarcinoma of the gastro-esophageal junction. The majority of them were well-differentiated being easily recognized by their submucosal invasion. We believe that surgery with curative intent is superior to curative palliative treatment.

Keywords: esogastric junction, adenocarcinoma, curative surgery.

Introduction

Because of its borderline location, between the stomach and esophagus, the choice of surgical strategy for patients with adenocarcinoma of the esogastric junction is controversial [1].

Accurate preoperative staging of cancer of the cardia requires computed tomography, endoscopic ultrasound; laparoscopy is useful for advanced cancer to detect liver and peritoneal metastasis, preventing an unnecessary laparotomy in up to 20% of patients.

The Siewert's classification of the esogastric junction cancer is internationally accepted: type I – tumor center within the last 5 cm of the distal esophagus, treated with subtotal esophagectomy; type II – located at the esogastric junction, treated with distal esophagectomy and, either proximal or total gastrectomy; and type III – subcardial cancer, treated by extended total gastrectomy [2, 3].

The classification of adenocarcinomas of the esogastric junction into type I, II, and III shows marked differences between the tumor types and provides a useful tool for selecting the surgical approach. For patients with type II tumors, esophagectomy offers no advantage over extended gastrectomy if a complete tumor resection can be achieved [1].

Materials and Methods

The study was carried out using 23 patients hospitalized in the General Surgery Clinic of the Emergency County Hospital of Craiova, between 2005 and 2010. All patients were diagnosed with adenocarcinoma of the esogastric junction through prior endoscopy and histopathological examination of the biopsies. Patients with resectable tumors underwent surgical resection followed by histopathological examination of the resected samples.

Tissue samples were immediately fixed in 10% buffered formalin solution and then processed through the usual paraffin-wax embedding technique. The paraffin blocks were cut using the microtome to 5 µm thick sections, which were then stained using the Hematoxylin–Eosin (HE) technique.

Results

Clinical study

The most frequently encountered tumor was represented by type III, subcardial adenocarcinoma, in 68% of all cases. Of the 14 patients with type III adenocarcinoma of the esogastric junction, nine were diagnosed with IIIb TNM stage, and five with stage IV

disease. Staging was performed after upper gastrointestinal endoscopy, echo-endoscopy and CT.

In six of the resectable cases, distal esophagectomy (resection border/limit was at 6 cm above the tumor) with total gastrectomy extended by abdominal transthoracic approach was performed; in three of the cases, distal esophagectomy with total gastrectomy extended by abdominal transhiatal subdiaphragmatic approach was performed. Significant frequency increase of fistula, both anastomotic and at the level of the gastric tube due to the use of a narrow gastric tube, determined the use of a larger gastric tube of 6 cm diameter to which pyloroplasty was associated.

One of the cases needed splenectomy due to the presence of a metastatic ganglionar mass along the splenic artery. Extemporaneous histopathological investigation of the esophageal segment was performed as it was necessary in the esogastric resection case, by an abdominal transhiatal approach.

As for the anastomosis we chose the terminal-lateral anastomosis to recover the digestive continuity after esogastric resection. In order to avoid gastric stasis and tracheobronchial aspiration syndrome during the immediate postoperative period, during the surgical procedure we placed a nasogastric probe that was kept for 2–3 days after surgery.

Histopathological aspects

All the studied cases were diagnosed with adenocarcinoma of the esogastric junction. The majority of them were well-differentiated (four cases), being easily recognized by their submucosal invasion (Figures 1 and 2). The inflammatory infiltrate present in all studied cases was predominantly represented by lymphocytes and plasma cells as markers of chronic inflammation and long disease evolution. The inflammation had a diffuse pattern in the mucosal chorion and was always associated with local vascular hyperemia (Figures 3 and 4).

The well-differentiated tumors generally had a one-way invasion towards the mucosa or deep in the muscle layers, while the less differentiated adenocarcinomas had a two-way invasion. One of the patients who underwent distal esophagectomy suffered a lethal complication, having a prior diagnosis of well-differentiated invasive adenocarcinoma of the esogastric junction (Figures 5).

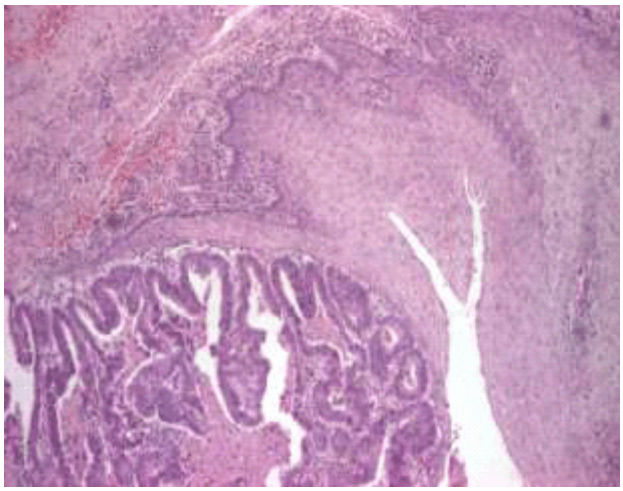

Figure 1 – ***Well-differentiated adenocarcinoma of the esogastric junction with invasion of the squamous epithelium and intense inflammatory reaction (HE stain, ×100).***

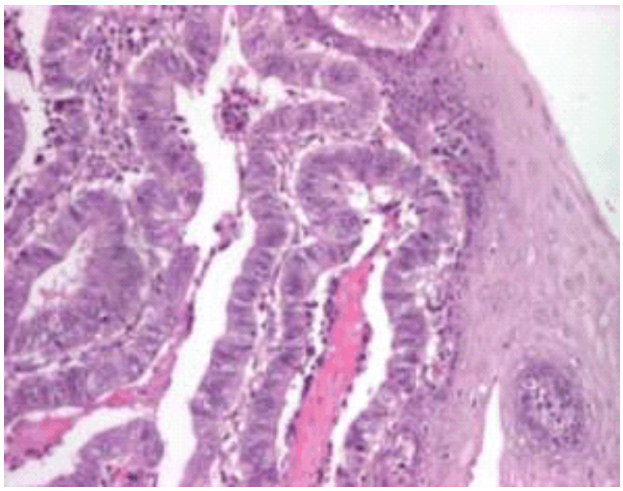

Figure 2 – ***The same case, detail (HE stain, ×200).***

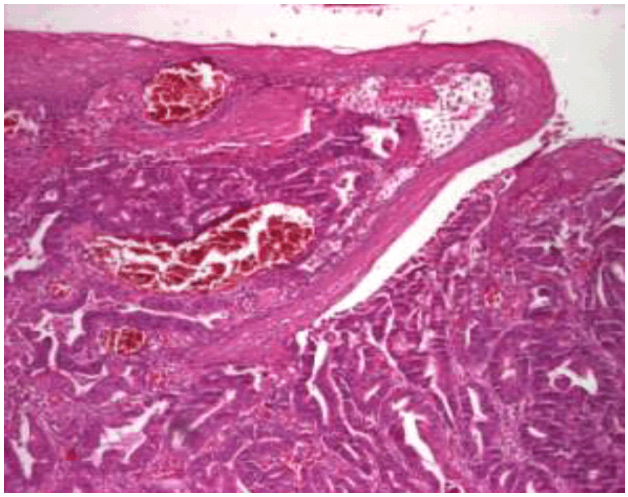

Figure 3 – ***Less differentiated adenocarcinoma with mucosal and muscle layer invasion (HE stain, ×100).***

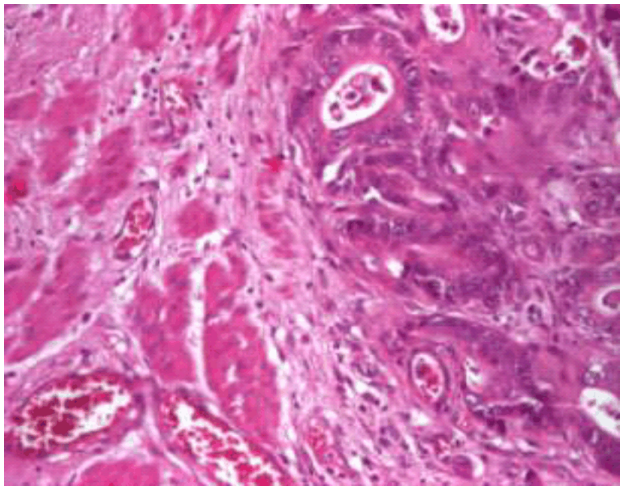

Figure 4 – ***The same case, detail (HE stain, ×200).***

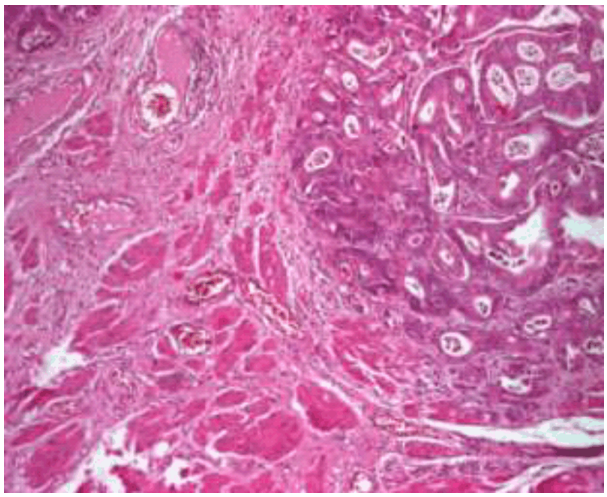

Figure 5 – ***A well-differentiated adenocarcinoma of the esogastric junction with muscle layer invasion (HE stain, ×100).***

Discussion

Most adenocarcinomas of the esophagus occur in the area of the cardia and originate in islands of gastro-intestinal mucosa, less often in the submucosal glands, and from the histological point of view are usually similar to gastric adenocarcinoma and its various histological patterns. Most tumors are well-differentiated [4].

It may be impossible to determine whether a cancer straddling the esogastric junction arose from the gastric cardia or the distal esophagus. Cancer in both sites is associated with gastroesophageal reflux disease (GERD) and Barrett's esophagus (BE). Cardia cancer shows the same secular trends, epidemiologic backgrounds, and molecular profiles as BE associated adenocarcinoma [5–7] and differs in this respect from monocardial gastric cancer [8].

Barrett's esophagus is a metaplastic transformation, which results from long-term gastro-esophageal reflux disease, being the consequence of the combination of some substances of the refloated contents including acids, bile salts, phospholipids and activated pancreatic enzymes. The interaction between these substances determines various degrees of lesion repairing, transforming and maturing the clinic phenotype in forms of esophagitis, Barrett's esophagus, strictures, dysplasia and carcinoma. In this abnormal environment, immature multi-potent stem cells differentiate into various epithelial types, including the columnar epithelium which is more resistant to acid digestion and which has a faster regeneration capacity than the one of native squamous epithelium. Once formed, Barrett's esophagus is a highly proliferate mucous [9].

The formation of Barrett's esophagus goes through at least three different phases. During the initiation phase, the genetically susceptible patients suffering from gastro-esophageal reflux disease develop reflux esophagitis, which leads to the formation of metaplastic epithelium, having the characteristics of intestinal columnar epithelium [9].

Adenocarcinomas usually arise in the distal esophagus from BE. BE-associated cancers account for more than 90% of esophageal adenocarcinomas.

Adenocarcinomas extensively infiltrate the esophageal wall and often show perineural invasion, lymphatic and vascular invasion, and direct extension through the esophageal wall. Lymph node metastases are present in 51% to 74% of cases [10]. The frequency of nodal metastasis correlates with the depth of tumor invasion. A study of 90 early cancers found no metastases among 36 mucosal tumors, three of 29 cancers that involved the muscularis mucosae or superficial submucosa (10%) and nine of 25 cases that penetrated to the deep submucosa (36%; $p<0.001$) [11].

Separated abdominal and left thoracic incisions give enough surgical/operatory field, also maintaining the integrity of both the costal margin and the diaphragm, but by performing an intrathoracic esojejunal anastomosis the patient is expected to be exposed to the risk of intra-thoracic fistula with lethal potential – this lead to the death of one patient.

Limited dissection of supratumoral esophagus using this procedure just after diaphragmatic pillar sectioning, and the tendency of submucous tumoral dissemination in the esophagus, could lead to the risk of an invaded esophageal segment [12, 13].

The prognosis of the esogastric junction carcinoma is worsened by the potential two-way route of spread in case of lymph node metastasis: mediastinum and abdomen. Some authors concluded that in all patients the five-year survival rate was 10.2%, improving to 15% in case of curative resection. The value of lymph node metastasis (80.7% of the patients) as a prognostic factor depended on the proximal or distal localization of the nodes. A positive surgical margin (15.7% of the patients) was a poor prognostic factor with a 6.9 months mean survival [14].

Aggressive medical or surgical antireflux therapy may ameliorate symptoms, but have not yet been proven to affect the risk of developing esophageal adeno-carcinoma in randomized trials. Although dysplasia is an imperfect biomarker for the development of subsequent malignancy, random sampling of esophageal tissue for dysplasia remains the clinical standard. There have been no studies to establish that endoscopic screening/surveillance programs decrease the rates of death from cancer. Fit patients with Barrett's esophagus and high-grade dysplasia should undergo esophagectomy to prevent the risk of developing esophageal adeno-carcinoma. For non-operative candidates, endoscopic ablative approaches may represent a reasonable therapeutic alternative [15].

Conclusions

For any histopathological type of adenocarcinoma of the esogastric junction, distal gastrectomy with distal esophagectomy extended by abdominal transhiatal approach allows the surgical approach of the type III esogastric-junction tumors in patients who have a poor biological status, and the risk of complications associated with intrathoracic fistula is removed. One

drawback of this approach is the fact that one cannot get a 6 cm supratumoral resection margin in order to achieve an R0 resection. Patients should be carefully supervised and investigated by a multi-disciplinary team (gastro-enterologist, pathologist and surgeon), in order to discover the invasive cancer in an early phase, thus increasing the survival chance. We believe that surgery with curative intent is superior to that with curative palliative visa.

References

[1] Rüdiger Siewert J, Feith M, Werner M, Stein HJ, *Adenocarcinoma of the esophagogastric junction: results of surgical therapy based on anatomical/topographic classification in 1,002 consecutive patients*, Ann Surg, 2000, 232(3):353–361.

[2] Triboulet JP, Fabre S, Castel B, Toursel H, *Adenocarcinomas of the distal esophagus and cardia: surgical management*, Cancer Radiother, 2001, 5(Suppl 1):90s–97s.

[3] Siewert JR, Stein HJ, *Classification of adenocarcinoma of the oesophagogastric junction*, Br J Surg, 1998, 85(11): 1457–1459.

[4] Koss LG, Melamed MR, *Koss' diagnostic cytology and its histopathologic bases*, Lippincott Williams & Wilkins, Philadelphia, 2006, 849–866.

[5] Dolan K, Morris AI, Gosney JR, Field JK, Sutton R, *Three different subsite classification systems for carcinomas in the proximity of the GEJ, but is it all one disease?* J Gastroenterol Hepatol, 2004, 19(1):24–30.

[6] Flucke U, Steinborn E, Dries V, Mönig SP, Schneider PM, Thiele J, Hölscher AH, Dienes HP, Baldus SE, *Immunoreactivity of cytokeratins (CK7, CK20) and mucin peptide core antigens (MUC1, MUC2, MUC5AC) in adenocarcinomas, normal and metaplastic tissues of the distal oesophagus, oesophago-gastric junction and proximal stomach*, Histopathology, 2003, 43(2):127–134.

[7] Ectors N, Driessen A, De Hertog G, Lerut T, Geboes K, *Is adenocarcinoma of the esophagogastric junction or cardia different from Barrett adenocarcinoma?* Arch Pathol Lab Med, 2005, 129(2):183–185.

[8] Stemmermann GN, Nomura AM, Kolonel LN, Goodman MT, Wilkens LR, *Gastric carcinoma: pathology findings in a multiethnic population*, Cancer, 2002, 95(4):744–750.

[9] Corina Maria Dochiţ, Cristiana Simionescu, Corina Gruia, Rodica Taslâcă, Diana Stănculescu, *Pathogenesis of esogastric junction cancer*, Current Health Sci J, 2010, 36(3):234.

[10] Paraf F, Fléjou JF, Pignon JP, Fékété F, Potet F, *Surgical pathology of adenocarcinoma arising in Barrett's esophagus. Analysis of 67 cases*, Am J Pathol, 1995, 18:183.

[11] Liu L, Hofstetter WL, Rashid A, Swisher SG, Correa AM, Ajani JA, Hamilton SR, Wu TT, *Significance of the depth of tumor invasion and lymph node metastasis in superficially invasive (T1) esophageal adenocarcinoma*, Am J Surg Pathol, 2005, 29(8):1079–1085.

[12] Ulrich B, Zahedi A, *Technical aspects and results of the transhiatal resection in adenocarcinomas of the gastro-esophageal junction*, Dis Esophagus, 2001, 14(2):115–119.

[13] Braghetto I, Csendes A, Cardemil G, Burdiles P, Korn O, Valladares H, *Open transthoracic or transhiatal esophagectomy versus minimally invasive esophagectomy in terms of morbidity, mortality and survival*, Surg Endosc, 2006, 20(11):1681–1686.

[14] Visset J, Couderc JP, Letessier E, Hamy A, Paineau J, *Cancer of the cardia. Prognostic factors and treatment*, Chirurgie, 1992, 118(9):541–545.

[15] Schuchert MJ, Luketich JD, *Management of Barrett's esophagus*, Oncology (Williston Park), 2007, 21(11):1382–1389, 1392; discussion 1392, 1394, 1396.

Corresponding author

Dragoş Ene, MD, Clinic of General Surgery, "Floreasca" Emergency Hospital, 8 Floreasca Avenue, Sector 1, 014461 Bucharest, Romania; Phone +4021–599 23 00, Fax +4021–599 22 57, e-mail: dragoshene@yahoo.com

Received: November 15th, 2011

Accepted: February 10th, 2012