

Bilateral extensor indicis brevis: a rare muscular variant

JING LI, ZHEN FENG REN

*Department of Anatomy,
Academy of Basic and Forensic Medicine,
Jining Medical University, Shandong, China*

Abstract

Variants on muscles and tendons of the forearm or hand occur frequently in human beings. They are often discovered during educational cadaveric dissections and surgical procedures. Knowledge of such anomalies is necessary to the surgeons in order to avoid possible damage to adjacent muscles' tendons' blood vessels or nerves. Here we describe a rare muscular variant, the extensor indicis brevis originating from the ligaments of the proximal row of dorsal carpal bones.

Keywords: extensor indicis, variant, clinical relevance.

☞ Introduction

The hand is an exquisite organ in human population for performing activities in everyday life. It is one of the most frequently used parts of our body. Therefore, the knowledge of muscles and tendons of hand and their common variants appears to be very important, especially when surgery is planned there. The fact is that the extensor muscles and tendons of the forearm and hand have great variability [1].

Komiyama M *et al.* [2] once classified the variants of supernumerary extensor indicis muscles or tendons into four types: an additional tendon slips from the extensor indicis tendon; an extensor indicis radialis or extensor pollicis et indicis accessorius; an extensor medii proprius with or without extensor medii brevis; an extensor indicis radialis and extensor medii proprius.

During routine dissection, Nayar R and McArthur P [3] found an accessory supernumerary tendon to the extensor indicis accompanied with an anomalous tendon to the thumb, creating a “Y” shape.

The most pattern of extensor indicis was a single tendon with one slip proximal to the extensor retinaculum, lying in an ulnar position to extensor digitorum communis-index finger [1].

In the present case, the bilateral extensor indicis have their origin different from the common condition. We report this unusual pattern of extensor indicis with the presence of short, flat muscle to the index finger.

☞ Materials and Methods

The study involved dissection of a 50-year-old male cadaver. The dissection of upper extremities carried out in the Department of Anatomy of Jining Medical University, Shandong, China.

The extensor retinaculum was exposed and the dorsum of the hands diligently dissected. The extensor tendons were delineated and followed to their insertions.

The tendons of the extensor digitorum, extensor indicis and extensor digiti minimi were studied respectively and an appropriate photograph was also taken.

The cadaver was preserved by the injection of formalin based preservative (10% formalin) and stored at -4°C.

☞ Results

In the present cadaver, the extensor digitorum divided into four tendons, which passed deep to the extensor retinaculum to the dorsum of hand and formed the dorsal digital expansions of the 2nd to 5th fingers. Each extensor expansion divided into three slips to insert the dorsal surface of the middle and distal phalanges respectively.

The left extensor indicis muscle belly originated from the joint capsule ligament and ran across the second dorsal interosseous muscle as a single tendon on the ulnar side of the extensor digitorum communis-index finger. The belly was 3.6 cm long, mean width 1.1 cm (Figure 1A).

The right extensor indicis muscle belly originated from the joint capsule and ligaments of scaphoid and lunate. It ran across the third metacarpal and the second dorsal interosseous muscle and inserted as a single tendon to the ulnar of index extensor digitorum communis tendon. It was innervated by the posterior interosseous nerve. The belly was 4.6 cm long, mean width 0.75 cm (Figure 1B).

We named the short, flat muscle belly with a single tendon to index finger as “extensor indicis brevis”.

☞ Discussion

In the human embryo, the precursor extensor muscle of the forearm differentiates into three parts. The radial portion differentiates into the brachioradialis, the extensor carpi radialis longus and the extensor carpi radialis

brevis. Then it divides into a superficial and a deep portion. The superficial portion forms the extensor digitorum communis, extensor carpi ulnaris and extensor digiti minimi. At the same time, the deep portion generates the abductor pollicis longus, the extensor pollicis brevis on the radial side with the extensor pollicis longus, extensor indicis on the ulnar side [4].

The superficial and radial groups are more stable with the major divisions of the phylum of the animal

species, while the deep portion appears to be highly unstable and undergoes evolutionary changes, as can be found in the great variation in its expression in different species of primates [5].

The extensor pollicis longus and extensor indicis developed phylogenetically from extensor pollicis et indicis. The accessory extensor pollicis et indicis coexisting with extensor pollicis longus and extensor indicis occurs in about 2% of population [6].

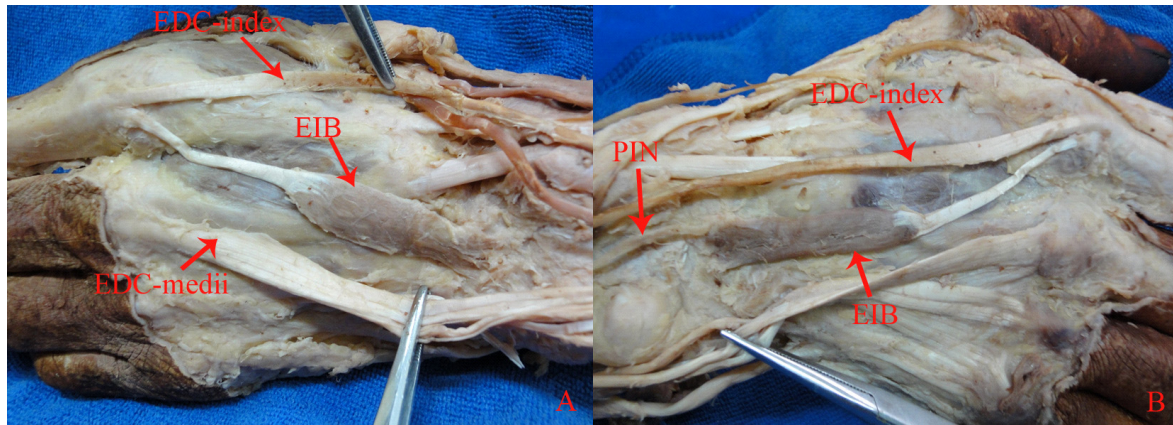


Figure 1 – Dissection of the dorsum of hands, showing the extensor indicis brevis. (A) Dorsum of the left hand: EIB – Extensor indicis brevis, EDC-index – Extensor digitorum communis to index finger, EDC-medii – Extensor digitorum communis to middle finger. (B) Dorsum of the right hand: EIB – Extensor indicis brevis, EDC-index – Extensor digitorum communis to index finger, PIN – Posterior interosseous nerve.

Usually, the origin of extensor indicis muscle arises from the proximal part of the distal third of the posterior surface of the ulnar, distal to that of the extensor pollicis longus. Variants of the extensor indicis are rare, including its absence and variants of origin or insertion [7, 8].

Gahhos FN and Ariyan S [9] once reported an extensor indicis brevis originating from the ligament of the scaphoid bone, which was uncommon.

Gebuhr P and Klareskov B [10] found that the extensor digitorum brevis extended distally beneath the extensor tendons as a single belly and inserted into the extensor mechanism of the ulnar side of the third finger. This was one kind of bilateral extensor digitorum brevis, but the insertion was different from the present case.

Cavdar S and Sehirlu U [11] reported a “band-shaped” muscle originating from the deep carpal fascia and inserted to the extensor tendons of the fourth and fifth fingers with a tendon and a slip respectively.

Cigali BS *et al.* [12] found an extensor digitorum brevis muscle originating from the distal end of the radius, carpal ligaments and carpal joint capsule and inserted on the tendon of the extensor digiti medii proprius.

In a detailed study of 559 dissected hands of 286 Japanese cadavers by Ogura T *et al.* [13], the extensor digitorum brevis muscle was found to arise from the posterior radiocarpal ligament near the lunate and frequently as far as proximal as the distal margin of the radius, but without direct attachment to the carpal bones.

According to a report on 263 upper limbs of cadavers, Cauldwell EW *et al.* [14] found that with the exception of three specimens, all the extensor indicis originated from the ulna. Two of the three muscles derived

secondary slips from the ulna while the third completely separated from it.

El-Badawi MG *et al.* [15] examined the pattern of extensor tendon on 181 hands and found one extensor indicis brevis replacing the proper muscle.

Yamaguchi S and Viegas SF [16] reported an extensor indicis tendon inserted to the radial of the extensor digitorum communis-index. In a study of 50 hands dissection, the extensor indicis tendon was always observed to lack a junctura tendinum. The extensor indicis was absent in both hands of only one cadaver [17].

Yalçın B *et al.* [18] examined the existence of the extensor indicis et medii communis in detail and observed three of sixty-two hands, an incidence of 4.8%.

The extensor digitorum brevis muscle was an aberrant finger extensor [19] and often discovered during surgical operations [20]. It may present as a swelling or tissue mass on the dorsum of the hand [21–25], resulting in pain of the wrist [26–28], and usually misdiagnosed as ganglion or soft tissue tumors [29–30]. Sometimes, surgical decompression of the fourth compartment may be required if conservative treatment failed [28].

Knowledge of these variants is not only important for differential diagnosis of doctors but also might eliminate a surgical procedure.

☞ Conclusions

Precise knowledge of possible variants of extensor tendons of the hand is vital for the success of reconstructive procedures in this region. Furthermore, accurate examination to this region requires profound familiarity with the variants of the extensor tendons.

References

- [1] Hirai Y, Yoshida K, Yamanaka K, Inoue A, Yamaki K, Yoshizuka M, *An anatomic study of the extensor tendons of the human hand*, J Hand Surg Am, 2001, 26(6):1009–1015.
- [2] Komiyama M, Nwe TM, Toyota N, Shimada Y, *Variations of the extensor indicis muscle and tendon*, J Hand Surg Br, 1999, 24(5):575–578.
- [3] Nayar R, McArthur P, *A supernumerary extensor tendon to the thumb with an accessory tendon to extensor indicis*, BMJ Case Rep, 2009, pii: bcr08.2008.0791.
- [4] Souter WA, *The extensor digitorum brevis manu*, Br J Surg, 1966, 53(9):821–823.
- [5] Wood FJ (ed), *The morphology of the extrinsic muscles*. In: *The principles of anatomy as seen in the hand*, 2nd edition, Bailliere, Tindall and Cox, London, 1946, 243–255.
- [6] Gaulke R, *The extensor pollicis et indicis: an accessory or rudimentary deep extensor tendon to the thumb? Variants – frequency – clinical relevance*, Handchir Mikrochir Plast Chir, 2001, 33(5):310–320.
- [7] Tan ST, Smith PJ, *Anomalous extensor muscles of the hand: a review*, J Hand Surg Am, 1999, 24(3):449–455.
- [8] Adler H, Schlenkhoff D, Seiler W, *M. extensor digitorum brevis of the hand. A contribution on an anomaly of hand extensor musculature*, Handchir Mikrochir Plast Chir, 1982, 14(4):251–252.
- [9] Gahhos FN, Ariyan S, *Extensor indicis brevis: a rare anatomical variation*, Ann Plast Surg, 1983, 10(4):326–328.
- [10] Gebuhr P, Klaeskov B, *Extensor digitorum brevis manus. A case report*, Acta Orthop Scand, 1987, 58(1):85–86.
- [11] Cavdar S, Sehirli U, *The accessory tendon of the extensor indicis muscle*, Okajimas Folia Anat Jpn, 1996, 73(2–3): 139–142.
- [12] Cigali BS, Kutoglu T, Cikmaz S, *Musculus extensor digiti medii proprius and musculus extensor digitorum brevis manus – a case report of a rare variation*, Anat Histol Embryol, 2002, 31(2):126–127.
- [13] Ogura T, Inoue H, Tanabe G, *Anatomic and clinical studies of the extensor digitorum brevis manus*, J Hand Surg Am, 1987, 12(1):100–107.
- [14] Cauldwell EW, Anson BJ, Wright RR, *The extensor indicis proprius muscle: a study of 263 consecutive specimen*, Quart Bull Northwestern Univ Med School, 1943, 17:267–269.
- [15] El-Badawi MG, Butt MM, al-Zuhair AG, Fadel RA, *Extensor tendons of the fingers: arrangement and variations – II*, Clin Anat, 1995, 8(6):391–398.
- [16] Yamaguchi S, Viegas SF, *Extensor indicis proprius tendon: case report of a rare anatomic variation*, Clin Anat, 2000, 13(1):63–65.
- [17] Zilber S, Oberlin C, *Anatomical variations of the extensor tendons to the fingers over the dorsum of the hand: a study of 50 hands and a review of the literature*, Plast Reconstr Surg, 2004, 113(1):214–221.
- [18] Yalçın B, Kutoglu T, Ozan H, Gürbüz H, *The extensor indicis et medii communis*, Clin Anat, 2006, 19(2):112–114.
- [19] Shaw JA, Manders EK, *Extensor digitorum brevis manus muscle. A clinical reminder*, Orthop Rev, 1988, 17(9):867–869.
- [20] Della Vella P, De Giovannini E, *A case of extensor indicis brevis manus muscle*, Chir Ital, 1985, 37(2):214–218.
- [21] Voigt C, Breyer HG, *The extensor indicis brevis muscle – a rare anatomic variant. A case example and critical review of the literature*, Handchir Mikrochir Plast Chir, 1989, 21(5): 276–278.
- [22] Døssing KV, *Clinical importance of the extensor digitorum brevis manus muscle. Case report*, Scand J Plast Reconstr Surg Hand Surg, 1994, 28(1):77–78.
- [23] Fakh RR, Thomas R, Mansour A, *The extensor digitorum brevis manus. A case report*, Bull Hosp Jt Dis, 1997, 56(2): 115–116.
- [24] Murakami Y, Todani K, *The extensor indicis brevis muscle with an unusual ganglion*, Clin Orthop Relat Res, 1982, 162:207–209.
- [25] Dunn AW, Evarts CM, *The extensor digitorum brevis manus muscle: a case report*, Clin Orthop Relat Res, 1963, 28:210–212.
- [26] Towfigh H, Klaes W, *Muscle abnormalities on the back of the hand and their differentiation from soft-tissue tumors*, Chirurg, 1982, 53(11):716–718.
- [27] Patel MR, Desai SS, Bassini-Lipson L, Namba T, Sahoo J, *Painful extensor digitorum brevis manus muscle*, J Hand Surg Am, 1989, 14(4):674–678.
- [28] Constantian MB, Zuelzer WA, Theogaraj SD, *The dorsal ganglion with anomalous muscles*, J Hand Surg Am, 1979, 4(1):84–85.
- [29] Lehrberger K, Tizian C, *The musculus extensor indicis brevis – often mistaken clinically for a ganglion*, Chirurg, 1984, 55(11):768–769.
- [30] Reeder CA, Pandeya NK, *Extensor indicis proprius syndrome secondary to an anomalous extensor indicis proprius muscle belly*, J Am Osteopath Assoc, 1991, 91(3): 251–253.

Corresponding author

Jing Li, Department of Anatomy, Academy of Basic and Forensic Medicine, Jining Medical University, Shandong–272067, China; Phone +86 0537 3616290, e-mail: lijing800912@yahoo.com.cn

Received: January 17th, 2012

Accepted: February 28th, 2012