ORIGINAL PAPER

RJME
Romanian Journal of Morphology & Embryology
http://www.rjme.ro/

Disseminated granuloma annulare: study on eight cases

V. PĂTRAŞCU[1)], CLAUDIA GIURCĂ[2)], RALUCA NICULINA CIUREA[2)], CLAUDIA VALENTINA GEORGESCU[3)]

[1)]*Department of Dermatology, University of Medicine and Pharmacy of Craiova*
[2)]*Clinic of Dermatology*
[3)]*Department of Pathology*
Emergency County Hospital, Craiova

Abstract

Granuloma annulare (GA) is classified as localized, generalized/disseminated, subcutaneous, and perforating types. The studies show connection with diabetes mellitus, lipidic metabolic disorders, malignant diseases, thyroid disorders, infections (HBV, HCV, HIV). We performed a retrospective study between 2010–2011, regarding disseminated GA (GAD), and the relationship between GAD and other comorbidities. We clinically and histologically diagnosed eight cases of GAD. The patients were also investigated for the diagnosis of associated diseases. The treatment included topical corticosteroids, antihistamines, Calcipotriol/Betamethasone, Tacrolimus 0.03%, Pentoxifylline, Hydroxychloroquine. Therapeutic response was assessed one month and three months after hospitalization. Our patients were five women and three men, aged 46–68 years, mean age 57.25 years, with a disease history of one year and a half (between three months and four years). The lesions occurred in the upper extremities (eight cases), distal extremities (three cases), cervical area (two cases), and trunk (five cases). In seven cases, we found annular appearance and one patient had disseminated small papules eruption. Associated pathology was diabetes mellitus type II (five cases), overweight and obesity (five cases), dyslipidemia (three cases), hypothyroidism (one case), rheumatoid arthritis (one case), external ear canal basal carcinoma (one case). Although there is controversy regarding the relationship between GAD and associated diseases, it is accepted that it is significantly associated with diabetes mellitus, also found in our study in five out of eight cases. We noticed obvious improvements after local and general treatment. It is confirmed that GAD is prevalent in women, over 40-year-old. GAD is often associated with diabetes and dyslipidemia, therefore it is necessary to investigate patients in this direction. The histopathological exam is essential for an accurate confirmation of GA.

Keywords: granuloma annulare, disseminated granuloma annulare, associated diseases.

Introduction

Granuloma annulare (GA) is a granulomatous inflammatory, self-limited dermatosis, often asymptomatic, which has many clinical forms: localized, generalized/ disseminated, subcutaneous, and perforating. Granuloma annulare was described by Colcott Fox in 1895.

Various studies showed that generalized or disseminated granuloma annulare (GAD) represents between 2.8% and 15% of all cases and is usually unmanageable to therapy. Associations have been described between GAD and diabetes mellitus, disorders of the lipid metabolism, malignant disease, thyroid disease, infections (VHC, VHB and HIV) [1].

There is disagreement on the relationship between GAD and diabetes mellitus, thyroid disease (autoimmune thyroiditis, toxic adenoma), malignancy (Hodgkin's and non-Hodgkin's lymphoma, chronic lymphocytic leukemia, lung and breast cancer), viral infections (HIV, HBS, HCV). We studied the coexisting pathology in eight cases of GAD.

Treatment for GAD is not standardized and often the disease is recalcitrant to administered therapy. Some improvements were obtained, though in isolated cases, with local corticosteroids, cryotherapy, phototherapy, Hydroxychloroquine, Dapsone, Cyclosporine, retinoids, etc., with no comparative studies. All our patients received general treatment and we evaluated the benefits of each combination.

Patients and Methods

We performed a retrospective study in our clinic, between 2010 and 2011, regarding disseminated/ generalized GA, with the aim to emphasize the epidemiological aspects, clinical evolution (before and after therapy), and the relationship between this disease and the existing pathology.

We clinically and histologically diagnosed eight cases with GAD. The patients were investigated (biologically and interdisciplinary) for the diagnosis of comorbidities. Patients were biologically investigated (CBC – complete blood count, glucose, glycosylated HB, erythrocyte sedimentation rate, HBs Ag, anti-HCV, HIV antibodies, cholesterol, triglycerides, total lipids, thyroxine-T4, TSH), in order to diagnose coexisting diseases. The treatment of our patients consisted of topical therapy with Clobetasol propionate 0.05% (five cases), Calcipotriol 50 μg/g / Betamethasone dipropionate 0.5 mg/g (two cases), Tacrolimus 0.03% (one case).

As a general therapy, they received Pentoxifylline 800 mg/day (eight cases), antihistamines (eight cases), Hydroxychloroquine 400 mg/day (two cases) (Table 1).

Table 1 – ***Treatment used for patients included in the study***

No. of cases	Local treatment	Systemic treatment
3	Clobetasol propionate 0.05%, once a day	Pentoxifylline 800 mg/day Desloratadine 5 mg/day
2	Clobetasol propionate ointment 0.05%, once a day	Pentoxifylline 800 mg/day Desloratadine 5 mg/day Hydroxychloroquine 400 mg/day
2	Calcipotriol 50 µg/g / Betamethasone dipropionate 0.5 mg/g, once a day	Pentoxifylline 800 mg/day Desloratadine 5 mg/day
1	Tacrolimus ointment 0.03%, twice a day	Pentoxifylline 800 mg/day Desloratadine 5 mg/day

Therapeutic response was assessed at one month and three months after hospitalization.

We clinically evaluated erythema and indurations of every lesion.

Results

Our eight patients were five women and three men, mean age 57.25 years (between 46–68-year-old) with a disease history of one year and a half (between three months and four years). The eruption was distributed to the upper extremities in eight cases, distal extremities in three cases, cervical area in two cases and on the trunk in five cases. The annular and arciform appearance was seen in seven cases and one patient had a micropapular disseminated eruption. Related diseases were: diabetes mellitus type II (five cases), overweight and obesity (five cases), dyslipidemia (three cases), hypothyroidism (one case), external ear canal basal carcinoma (one case), rheumatoid arthritis (one case).

In all our patients, the eruption interested the upper limbs (Figure 1). In three cases, the lesions were present on the legs, the other two in the cervical region, while on the trunk we found lesions in five patients (Figure 2).

The clinical aspect that we found in seven cases consists from multiple arciform or annular lesions, 1–5 cm diameter, with coalescence small, firm, skin-colored or erythematous papules on the borders. One patient had a disseminated micropapular eruption in which histopathological exam confirmed the diagnosis. Although the clinical appearance is often suggestive, histopathological exam allows precision of the diagnosis and eliminates confusion with other diseases. We performed skin biopsy in all cases.

Histopathological examination of our cases revealed the following aspects: the lesions were usually present in the middle and superficial dermis and were characterized by the presence of granulomas with sparsely arranged histiocytes, surrounding necrobiotic collagen. We noticed rare multinucleated cells in the infiltrate, nearby degenerated collagen (Figures 3 and 4). In our cases, lymphocytic infiltrate was distributed mainly perivascular and we noticed there are fibrinoid deposits in the vessel walls and as a result, we notice a vascular luminal occlusion, as a distinguishing criterion for GA diagnosis (Figure 5).

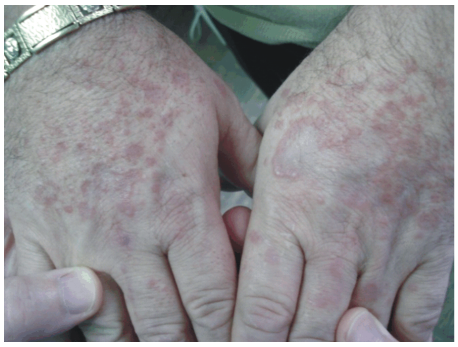

Figure 1 – ***Disseminated granuloma annulare: lesions on hands.***

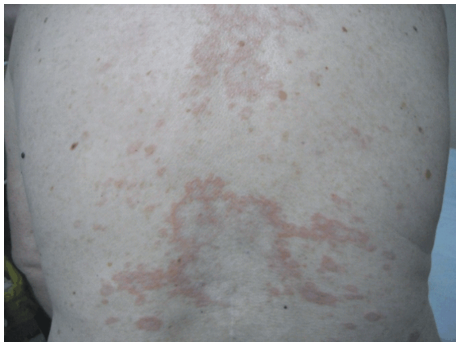

Figure 2 – ***Disseminated granuloma annulare: lesions on trunk.***

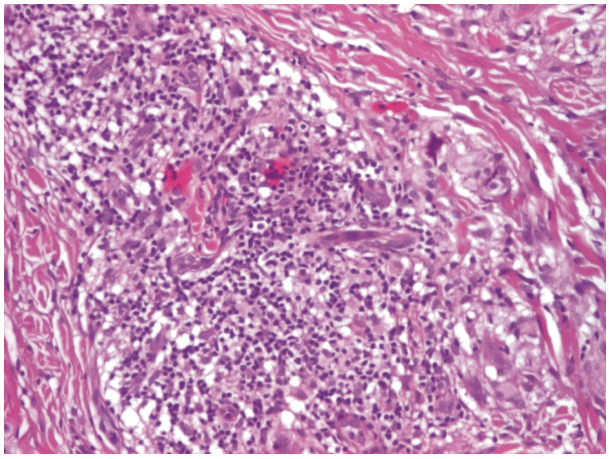

Figure 3 – ***Multinucleated cells and histiocytes in the infiltrate, nearby degenerated collagen (HE stain, ×100).***

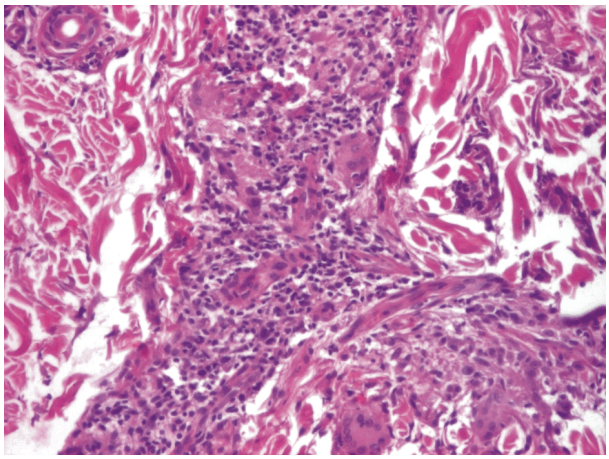

Figure 4 – ***Multinucleated cells in the infiltrate, nearby degenerated collagen (HE stain, ×100).***

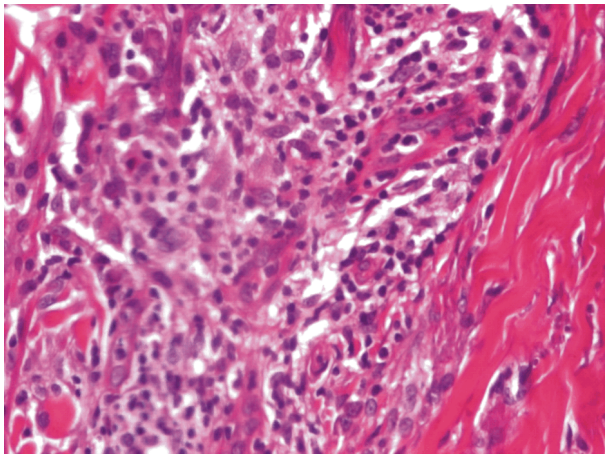

Figure 5 – ***Perivascular lymphocytic infiltrate and fibrinoid deposits in the vessel wall with vascular luminal occlusion (HE stain, ×200).***

Discussion

Granuloma annulare is a chronic dermatosis, who is clinical and histopathological aspects are usually distinctive. GA can occur twice as frequently in women [2], which is more characteristic for GAD. Localized form is more frequently diagnosed under the fourth decade. GAD has a bimodal distribution: children under 10-year-old and persons between 30–60-year-old. Subcutaneous GA may occur in adults, but it is more predominant in children 2–10-year-old. Perforating form affects regularly children. In our study group, the F/M ratio was 5:3, mean age 57.25 years, similar data to those in the literature.

Proportion of GAD differs after various authors, so according to Reisenauer A *et al.* [3], proportion is about 15%, while other authors [4] give values around 2.8–5.7%. According to the Mayo Clinic GAD represents 8.9% of all patients with GA [4].

GA manifests with flesh-colored or erythematous papules, often disposed in annular form, located frequently on the extremities. The lesions enlarge centrifugally and most of the time they are asymptomatic. The approximate distribution of GA lesions is 60% isolated to the hands and arms, 20% on the legs and feet, 7% on both upper and lower extremities, 5% on the trunk, and 5% on the trunk plus other areas. Facial lesions are rare.

GAD manifests with papules or nodules, lesions disposed on many parts of the body. The lesions may join together in plates (3–6 cm), which enlarge centrifugally in weeks/months.

Although they may appear in any part of the body, the lesions tend to be symmetrical on the extremities and trunk. Pruritus may be persistent. In all our patients the eruption involved the upper limbs. In three cases lesions were present on the legs too, the other two in the cervical region, while on the trunk we found lesions in five patients. Two special types of GA have been described: subcutaneous and perforating. Subcutaneous GA manifests with firm nodules, pink or erythematous, frequently located on the lower extremities (anterior tibial surfaces). Perforating GA, first time described by Owens and Freeman in 1971, represents less than 5% of GA. It may be located on any part of the body, but most frequently on extension limbs, the dorsal hands and fingers. Some are pruriginous, other are painful. Initially they appear as erythematous or skin-colored papules, and then further develop pustules releasing a clear, sticky fluid. However not all lesions become perforating. Some of them heal without scars. In 17–30% of the cases of perforating GA, we noticed an association with diabetes mellitus. As for evolution, spontaneous remission was noticed in 77% of cases in 3–4 years. Different treatments had variable success. For the treatment of single lesions, excision was used without relapses [5]. The histopathological exam of GA allows precision of diagnosis and eliminates clinical confusion with other diseases such as: miliaria rubra, pityriasis rubra pilar, cutaneous deposition disease (amyloidoses, mucinoses), lichen planus, tuberculides, erythema migrans, tinea corporis, tertiary syphilis or particular forms of mycosis fungoides.

From the histopathological point of view, non-infectious granulomas have been categorized into: epithelioid (sarcoid and tuberculoid), necrobiotic or palisading (granuloma annulare and others), and histiocytic or by foreign body.

GA is represented by a variable histiocyte and lymphocyte perivascular infiltrate. In most cases, GA is characterized by the presence of granulomas consisting of histiocytes that are not or slightly palisaded, or arranged in a palisadic pattern, surrounding necrobiotic collagen. The latter is usually represented by deposits of mucin and rarely fibrin. Often, histiocytes may become epithelioid multinucleated cells and may engulf elastic fibers. Histiocytes may be localized only interstitial, without apparent organization, or they may be ordered as palisades surrounding mucin areas. The aspects of granuloma annulare may vary between these two classical models, so a single biopsy may contain histiocytes that are not palisaded, that are slightly palisaded, or that are well palisaded. Collagen is present and also small quantities of degenerated fibrin. The hallmark of GA is mucin. Special stains to highlight mucin, if it is not clearly visible on conventional Hematoxylin–Eosin stain, are colloidal iron and Alcian Blue.

Plasma cells are less often present in the GA, and in a small percentage of biopsies we can talk about an infiltrate with eosinophils. We can state that the multinucleated histiocytes are present in the majority of GA, but usually they are few and often difficult to identify. Occasionally, it can be seen that they have engulfed thick elastic fibers, blue-gray stained. A histiocyte infiltrate is frequently current on all thickness of the dermis or in the middle and superficial dermis.

Vascular changes in GA may be different, but usually they are not very noticeable. In some cases, however, there are fibrinoid deposits in the vessel walls and as a result, we notice a vascular luminal occlusion.

Histopathologically, differential diagnosis is necessary to be made with some lesions which can mimic GA.

Rarely, in the GA there is an agglomeration of epithelioid histiocytes, usually giant cells, and a rim of lymphoid cells in the periphery, which recalls the aspect of sarcoidosis, differing in that they are less well-circumscribed and are missing the asteroid bodies [6].

Nearly all cases of GA show histiocytes diffusely

arranged among the present collagen bands, with the existence of small areas of mucin. Such cases should be distinguished from the necrobiosis lipoidica, which is characterized by a diffuse arrangement of histiocytes, which tend to affect the entire deep dermis [7, 8]. In necrobiosis lipoidica there is a larger number of giant cells, more obvious vascular changes and the prevalence of the plasma cells into the deep dermis; may present extensive deposits of lipids and nodular subcutaneous or deep dermis lymphocytic infiltrates [9, 10].

Interstitial type of GA can be confused with inflammatory stage of morphea, because of the palisades of the histiocytes, which are not well developed. A histiocyte infiltrate with interstitial distribution allows demarcation.

Interstitial type of GA can be similar to a xanthoma, but in GA, the foamy histiocytes are absent or very rare, while they are the main feature of the xanthoma. The GA lymphocytic infiltrate tends to be distributed mainly perivascular but not also in xanthomas.

Demarcation between a subcutaneous GA and a rheumatoid nodule is not always achievable on usual stains, but GA is mucin-rich and the foreign body giant cells and fibrinoid are less obvious.

A cutaneous T-cell lymphoma may present a granulomatous infiltrate similar to GA, but it can be recognized by the presence of an epidermotropism, consisting of a dermal lymphocytic infiltrate around superficial plexus and a lichenoid component of the infiltrate.

Epithelioid sarcoma may also contain mucin. The features for histopathologic diagnosis of epitheliod sarcoma are the recurrence, ulceration, necrosis areas that comprise the epithelioid cells and obviously, cytologic atypia: pleomorfism nuclear hyperchromasia, more atypical mitoses, are larger and have a more eosinophilic cytoplasm then the histiocytes of GA [11, 12].

Etiopathogenesis of GA is unclear. The following hypotheses have been issued: microangiopathy, auto-immune vasculitis, delayed-type of hypersensitivity, fault of neutrophil migration with accumulation of abnormal neutrophil, β-glucuronidase high serum titer, involved in degradation of mucopolysaccharides.

Inflammatory infiltrate from GA consists in macrophages and CD3+ cells [13]. There was a high prevalence of HLA Bw35 and A29 in patients with generalized GA compared with located GA [2, 14].

Certain trigger factors such as: insect bites, BCG vaccination, B or C hepatitis viruses, α-interferon treatment for hepatitis C virus infection, HPV, HIV, Epstein Barr virus, Varicella–Zoster virus have been discussed. Sun exposure is controversial. However, it was noted a case of generalized GA after exposure to PUVA therapy, although this represents an alternative therapeutic for generalized form of GA. Granuloma annulare lesions have a predilection for sun exposed areas.

In the group of studied patients, in all cases, we found lesions on the back of the hands and forearms, which make us to accept the sun as a pathogenic factor for this dermatosis.

Drugs like Allopurinol, calcium blockers, Calcitonin, anti-TNF-α, some chemotherapeutics, Topiramate, Amlodipine are involved in the appearance of GA lesions. The interval of GA occurrence after drugs is between five days and nine years [15].

As for the association with another disease, recent studies showed association with diabetes mellitus for localized and disseminated or generalized GA.

Thomas DJ *et al.* presented one case of GA, insulin-dependent diabetes mellitus and endocrine disease, which had a good evolution with diabetic control [16].

Another common association is with thyroid disease. In one case of generalized GA associated with auto-immune thyroiditis, the skin lesions improved at the moment of fading of anti-thyroid antibodies and restoration of the euthyroid state [17]. Generalized GA has been reported in a patient with a toxic adenoma of the thyroid (Plummer's disease) [18].

The connection of GA with malignant diseases (Hodgkin's and non-Hodgkin's lymphoma, chronic lymphatic leukemia, lung and breast cancer) has been described [19].

GAD is the most frequent form of GA seen in HIV-positive patients. Cases of generalized GA in patients with deficient immunity have been described.

Finally, the association of GA with necrobiosis lipoidica and sarcoidosis was reported.

In our study, the most frequently associated disease was diabetes mellitus (five cases). In four patients, the diabetes preceded by three to 11 years the lesions of disseminated GA, in one case the diabetes was diagnosed after. In all our patients, diabetes type 2 was associated (glucose between 180–210 mg/dL and HBA1c between 7.7–8.3%); they were obese or overweight person.

As for the correlation between GA and diabetes mellitus, some authors consider that collagen alteration which diabetes mellitus produces is the main cause of GA [20].

Also as associate disease, we found three cases of dyslipidemia (triglycerides 180–235 mg/dL, cholesterol 220–290 mg/dL), one case of hypothyroidism (T4 41 nmol/L; TSH 5.1 μIU/mL), one case of rheumatoid arthritis, and one case of external ear canal basal carcinoma.

One study on a group of 100 GA cases revealed that 45% of them had lipidic anomaly, (hypercholesterolemia, hypertriglyceridemia or both) [3].

In our study, in three cases dyslipidemia preceded the GA lesions with several months or years.

Local treatment was topical Clobetasol propionate 0.05% in five cases, Calcipotriol 50 μg/g / Betamethasone dipropionate 0.5 mg/g in two cases, Tacrolimus 0.03% in one case. General treatment was Pentoxifylline in eight cases, antihistamines in eight cases, Hydroxy-chloroquine in two cases. We acquired improvements in six cases; results were more obvious in the two cases treated with local steroids, Pentoxifylline and anti-malaria drugs. Simultaneously all patients received treatment for associated pathology.

Lesions of localized GA may disappear spontaneously. Local corticoids can be currently used, but usually with poor results. There can be usually used also intralesional

steroids, cryosurgery, and injections with low-dose recombinant gamma interferon, photodynamic therapy, laser therapy and, with some favorable results, dotted electrocauterization. For generalized GA, PUVA-therapy, and UVB phototherapy in combination with Tranilast [21] have proved to be effective. There are few reports mentioning the use of Cyclosporine with good results [3].

Shupack J and Siu K [22] reported the disappearance of generalized GA lesions after Etanercept, although in a series of four patients presented by Kreuter A *et al.* [23] there was no change in lesions during treatment with the same agent.

Some cases of GA, which occurred in the context of immunosuppression, had a positive development after the restoration of immunity [24].

Conclusions

It is confirmed that GAD is prevalent in women and people over 40-year-old. GAD is often associated with diabetes mellitus and dyslipidemia, which incite us to investigate patients in this direction. The histopathological exam allows certain diagnosis of the GA lesions and eliminates clinical misdiagnoses. However, with no comparative studies, it is difficult to draw conclusions on the effectiveness of therapeutic means, especially since in 50–70% localized GA spontaneous remissions in the first two years of disease has been observed. GAD is more resistant to topical and systemic therapy.

References

[1] Pătraşcu V, *Boli dermatologice şi infecţii sexual-transmisibile*, ediţia a II-a, Ed. SITECH, Craiova, 2012, 548–549.

[2] Burns DA, Necrobiotic disorders. In: Burns T, Breathnach S, Cox N, Griffiths C (eds), *Rook's textbook of dermatology*, vol. 1, 8th edition, Blackwell Publishing, 2012, 3078–3098.

[3] Reisenauer A, White KP, Korcheva V, White C Jr, Non-infectious granulomas. In: Bolognia J, Jorizzo JL, Schaffer JV (eds), *Dermatology*, 3rd edition, Elsevier–Saunders, 2012, 1557–1572.

[4] Werchau S, Enk A, Hartmann M, *Generalized interstitial granuloma annulare – response to adalimumab*, Int J Dermatol, 2010, 49(4):457–460.

[5] Billet A, Viseux V, Chaby G, Dascotte-Barbeau E, Gontier MF, Denoeux JP, Lok C, *Granulome annulaire perforant unique avec phénomène d'élimination transfolliculaire*, Ann Dermatol Vénéréol, 2005, 132(8–9 Pt 1):678–681.

[6] Chaitra V, Inchara YK, Rajalakshmi T, Antony M, *Granuloma annulare – histology reconsidered*, Indian J Dermatol Venereol Leprol, 2010, 76(5):568–569.

[7] Christine JK, Glusac EJ, Shapiro PE, Noninfectious granulomas. In: Elder DE, Elenitsas R, Johnson BL, Murphy GF, Xu X (eds), *Lever's histopathology of the skin*, 9th edition, Lippincott Williams & Wilkins, Philadelphia, 2009, 361–364.

[8] Weedon D, Strutton G, Rubin AI, The granulomatous reaction pattern. In: Weedon D (ed), *Weedon's skin pathology*, Churchill Livingstone–Elsevier, Philadelphia, 2010, 177–181.

[9] Crosby DL, Woodley DT, Leonard DD, *Concomitant granuloma annulare and necrobiosis lipoidica. Report of a case and review of the literature*, Dermatologica, 1991, 183(3):225–229.

[10] Lowitt MH, Dover JS, *Necrobiosis lipoidica*, J Am Acad Dermatol, 1991, 25(5 Pt 1):735–748.

[11] Cyr PR, *Diagnosis and management of granuloma annulare*, Am Fam Physician, 2006, 74(10):1729–1734.

[12] Kowalzick L, *Granuloma annulare*, Hautarzt, 2005, 56(11): 1071–1081; quiz 1082.

[13] Lagier L, Dunoyer E, Esteve E, *Le topiramate: un nouvel inducteur de granulome annulaire?* Ann Dermatol Vénéréol, 2011, 138(2):141–143.

[14] Boyd AS, *Granuloma annulare responsive to oral calcitriol*, Int J Dermatol, 2012, 51(1):120–122.

[15] Sioud Dhrif A, Dalle S, Balme B, Jullien D, Thomas L, *Lésions papuleuses diffuses*, Ann Dermatol Vénéréol, 2008, 135(1): 74–77.

[16] Thomas DJ, Rademaker M, Munro DD, Levison DA, Besser GM, *Visceral and skin granuloma annulare, diabetes, and polyendocrine disease*, Br Med J (Clin Res Ed), 1986, 293(6553):977–978.

[17] Willemsen MJ, de Coninck AL, Jonckheer MH, Roseeuw DI, *Autoimmune thyroiditis and generalized granuloma annulare: remission of the skin lesions after thyroxine therapy*, Dermatologica, 1987, 175(5):239–243.

[18] Tursen U, Pata C, Kaya TI, Dusmez D, Ikizoglu G, *Generalized granuloma annulare associated with Plummer's disease*, J Eur Acad Dermatol Venereol, 2002, 16(4):419–420.

[19] Ine K, Kabashima K, Koga C, Kobayashi M, Tokura Y, Kabashima K, *Eruptive generalized granuloma annulare presenting with numerous micropapules*, Int J Dermatol, 2010, 49(1):104–105.

[20] Kakourou T, Psychou F, Voutetakis A, Xaidara A, Stefanaki K, Dacou-Voutetakis C, *Low serum insulin values in children with multiple lesions of granuloma annulare: a prospective study*, J Eur Acad Dermatol Venereol, 2005, 19(1):30–34.

[21] Derancourt C, Semser M, Atallah L, Becker MC, Laurent R, *Granulome annulaire des zones photo-exposées chez deux malades ayant eu une greffe hépatique*, Ann Dermatol Vénéréol, 2000, 127(8–9):723–727.

[22] Shupack J, Siu K, *Resolving granuloma annulare with etanercept*, Arch Dermatol, 2006, 142(3):394–395.

[23] Kreuter A, Altmeyer P, Gambichler T, *Failure of etanercept therapy in disseminated granuloma annulare*, Arch Dermatol, 2006, 142(9):1236–1237; author reply 1237.

[24] Jacobi D, Rivollier C, Buisson H, de Muret A, Besnier JM, Lorette G, *Granulome annulaire généralisé: guérison au cours du traitement d'une infection par le VIH*, Ann Dermatol Vénéréol, 2005, 132(3):243–245.

Corresponding author

Virgil Pătraşcu, Associate Professor, MD, PhD, Department of Dermatology, Faculty of Medicine, University of Medicine and Pharmacy of Craiova, 2 Petru Rareş Street, 200349 Craiova, Romania; Phone +40724–273 676, e-mail: vm.patrascu@gmail.com

Received: January 15th, 2013

Accepted: April 25th, 2013