ORIGINAL PAPER

RJME Romanian Journal of Morphology & Embryology http://www.rjme.ro/

Evaluation of the wound-healing effect of a novel *Hypericum perforatum* ointment in skin injury

ANCA IRINA PRISĂCARU[1)], C. V. ANDRIŢOIU[2)], CORINA ANDRIESCU[3)], E. C. HĂVÂRNEANU[4)], M. POPA[1)], A. G. M. MOTOC[5)], ANCA SAVA[6)]

[1)]*Department of Natural and Synthetic Polymers*
[2)]*Department of Chemical Engineering*
"Gheorghe Asachi" Technical University, Iassy
[3)]*Department of Pathological Anatomy and Prosecture,*
"Sf. Spiridon" Municipal Clinical Emergency Hospital, Iassy
[4)]*Faculty of Psychology and Education Sciences,*
"Alexandru Ioan Cuza" University, Iassy
[5)]*Discipline of Anatomy and Embryology,*
"Victor Babeş" University of Medicine and Pharmacy, Timisoara
[6)]*Discipline of Anatomy and Embryology,*
"Grigore T. Popa" University of Medicine and Pharmacy, Iassy

Abstract

The present experiment aims to formulate and characterize a new phytotherapy ointment based on a total extract of *Hypericum perforatum* included in a novel ointment base. In order to investigate the healing properties of the ointment, *in vivo* experimental wound models of linear incision, circular excision and thermal burn were performed on Wistar rats. Topical treatment was achieved daily, for 21 days. Clinical and macroscopic evaluation, determination of wound contraction rate, period of re-epithelialization, and histopathological examination were achieved, along with the determination of the particle diameter and particle size distribution of the ointment. The results demonstrate that the tested novel ointment has significant wound healing effect in skin injuries and reveals to be safe for use.

Keywords: *Hypericum perforatum*, incision, excision, thermal burn, wound-healing effect.

Introduction

Cutaneous wounds are the result of a disruption at the level of skin integrity. The healing process depends on local wound factors, systemic mediators, the underlying disease, and the type of injury, involving a series of well-organized cellular and molecular events, including inflammation, angiogenesis, fibroplasia, wound contraction, epithelialization, and matrix remodeling. These factors combine to determine if physiologic or acute wound healing occurs, or if there is an abnormal healing process, also called chronic wound healing. If the process of tissue repair following an inadequate treatment fails, they become chronic wounds. Besides the fact that these chronic dermal injuries affect negatively the quality of patients' life, their management and care need high economical resources, a rather important problem especially for the developing countries [1].

The basic principle of optimal wound healing is to minimize tissue damage and provide adequate tissue perfusion and oxygenation, proper nutrition and moist wound healing environment to restore the anatomical continuity and function of the affected part [2]. The last decades bring natural remedies into the medical forefront, having as major role the use of plants in the treatment of different disorders. The concept of phytotherapy treatment is reconsidered by achieving *in vivo* and *in vitro* studies regarding the confirmation of the healing effects of plants, the determination of the active principles responsible for these effects, and the elucidation of their mechanism of action [3–5].

The present experiment aims to formulate and prepare a novel ointment based on the total extract of the aerial parts of St. John's wort, to determine the particle diameter and particle size distribution and to evaluate its efficacy in the re-epithelialization processes on three *in vivo* experimental models (incision, excision, and thermal burn).

Materials and Methods

Chemical and materials

Ethyl alcohol, petrolatum, lanolin, and olive oil (*Olivae oleum virginale*) were purchased from Sigma-Aldrich. The aerial parts of *Hypericum perforatum* (St. John's wort) were collected from the Botanical Garden, Iassy, Romania, and a voucher specimen was identified by the staff of the same institution.

Preparation of the ointment

After collection, the plant material was dried in a dark room with controlled temperature and relative humidity.

Samples of the dried plant material with moisture content of 10% were mechanically ground to obtain a homogenous drug powder. The oil extract was prepared by weighting an amount of 50 g powder that afterwards was macerated in 500 mL of virgin olive oil in dark brown jars, at room temperature, for two weeks. The ethanol extract was obtained by weighting another quantity of 50 g powder that was macerated in 500 mL of 70% ethanol oil in dark brown jars, at room temperature, for two weeks. In the end, the extracts were filtered through gauze and placed in dark brown jars with stoppers. The ointment base was prepared by mixing petrolatum and lanolin in equal amounts on water bath (40^0C) until a homogenous base was obtained. Fifteen mL of *Hypericum* oil extract and 15 mL of *Hypericum* ethanol extract were gradually included into the ointment base, until homogenization was complete.

Determination of the particles size distribution

Particles size distribution was measured on an aqueous sample dispersion using a laser diffraction analyzer (Shimadzu SALDI-7001), with a refractive index of 1.60–0.10i.

Experimental models of dermal injury

Animals and housing

The experiment was unfolded on adult male rats, Wistar strain, having a body weight of 220–250 g. The animals were kept in a light and temperature-controlled room with 12:12 hours light–dark cycles, where the temperature (22 ± 0.5^0C) and relative humidity (65–70%) were kept constant. Each rat was kept in a separate cage with free access to standard laboratory diet and water.

All the experimental proceedings achieved on laboratory animals (Wistar rats) in this study were in agreement with the guidelines of animal bioethics from the Act on Animal Experimentation and Animal Health and Welfare Act from Romania and were in compliance with the European Council Directive of 24 November 1986 (86/609/EEC). The experiment was approved by the Ethics Commission of the "Grigore T. Popa" University of Medicine and Pharmacy, Iassy.

Study design

The experiment included three groups of Wistar rats (seven animals per group): negative control group (control group with incision, excision and thermal burn models, not treated), *Hyperici herba* ointment group (treated with the tested *Hyperici herba* ointment), and ointment base group (treated with the ointment base). Before performing the experimental models, the animals were anesthetized with Ketamine i.p. (100 mg/kg) and the hairs on the dorsal part of the rats were shaved and cleaned with 70% alcohol.

Three experimental wound models (linear incision, circular excision, thermal burn) were achieved on each animal. The incision wound model applied in this study was based on a previously described model [6], with some modifications. Two linear paravertebral incisions (1 cm long) were made with a sterile surgical blade through the full thickness of the skin at the distance of 1.5 cm from the midline of each side of the vertebral column. The excision wound model used in this study was based on a previously described model [6], with some modifications. The circular wound was created on the dorsal interscapular region of each animal by excising the skin with an 8 mm biopsy punch; wounds were left open. The burn model used in the present study was based on a previously described model [7], with some modifications. The original tip of a 40 W soldering iron was replaced with a square copper plate measuring 9×8 mm and brought to 100^0C. A laser high performance non-contact thermometer (Raynger MX4) was used to measure the desired temperature. The device was placed vertically under its own weight on the back of the rats for nine seconds, in order to induce a deep-partial thickness burn. Immediately after each burn injury, the wound was rinsed with normal saline solution [7].

The *Hyperici herba* ointment and the ointment base were applied topically once a day for 21 days, until the complete healing of the wound.

Evaluated parameters

Clinical and macroscopic evaluation, determination of wound contraction rate, period of re-epithelialization, and histopathological examination were performed at days 1, 2, 3, 6, 9, 12, and 21 of treatment. In the end, a specimen sample of tissue removed from the healed skin of all rats was taken with a 3 mm biopsy punch in order to be analyzed by histopathological examination.

Clinical evaluation

Clinical examination evaluated the following parameters: edema, inflammatory infiltrate, congestion, formation and falling of the scab, the type of scar.

Measurement of wound contraction rate (WCR)

The wound contraction rate (WCR) was calculated as the percentage of the original wound size (50.27 mm^2) for each animal on days 6 and 9, as shown in formula:

$$WCR = \frac{A_0 - A_t}{A_0} \times 100\%$$

where

A_0 – Initial area of wound at day "0" of experiment;

A_t – Area of wound at day "*t*" of experiment.

Digital photography was used to capture all wounds at days 1, 2, 3, 6, 9, 12, 21, and wound surface areas were measured in mm^2 with SigmaScan software (SigmaScan Ro, version 5.0).

Measurement of period of re-epithelialization

Falling of scab leaving no raw wound behind was taken as the end-point of complete epithelialization and the days required for this were taken as period of epithelialization.

Histopathological examination

In order to collect the samples of the healed skin for the ascertainment of the epithelialization process, animals were anesthetized with Ketamine i.p. (100 mg/kg). The collected samples were fixed in 10% buffered formalin for at least 24 hours, progressively dehydrated in solutions containing an increasing percentage of ethanol (60, 80, 90, and 98%, v/v), clarified with amyl alcohol, embedded

in paraffin under vacuum, sectioned at 5 μm thickness, deparaffinized, and stained with Hematoxylin–Eosin (HE) and Szekely (Sz).

Statistical analysis

The data obtained from excision wound model were analyzed by one-way ANOVA followed by Bonferroni post-test. Statistical analysis was performed using SPSS 15, where $p<0.05$ was considered statistically significant.

Results

Determination of the particles size distribution

The result of the laser diffraction measurement for the average diameter of the dispersed particles for the *Hyperici herba* ointment is shown in Figure 1 and Table 1. The mean values expressed as number distribution and volume distribution show that 75% of the number of particles have a size of 249 nm.

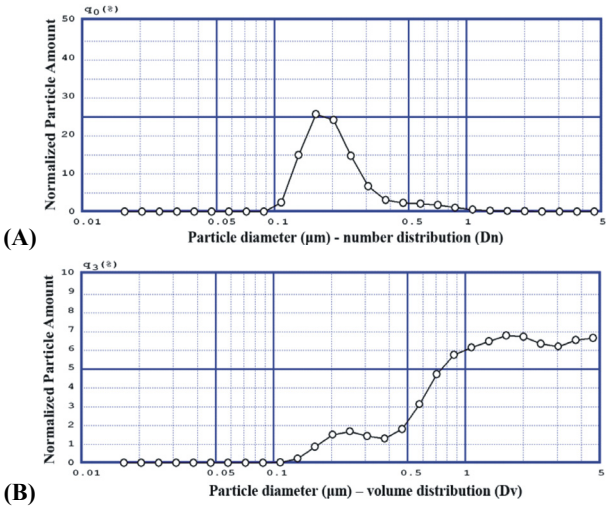

Figure 1 – ***Laser diffraction diagrams of the average diameter for the Hyperici herba ointment: (A) Number distribution; (B) Volume distribution.***

Table 1 – ***Particles size distribution for the Hyperici herba ointment***

Dimension of particle amount [μm]	Mean	25%D	50%D	75%D
Number distribution (D_n)	0.215	0.159	0.193	0.249
Volume distribution (D_v)	2.304	1.064	2.375	5.398

Clinical and macroscopic results

The macroscopic evaluation of epidermal lesions for the *Hyperici herba* ointment group demonstrated the efficacy of the treatment with the novel ointmentt containing the total extract of St. John's wort. The complete healing occurred after six days of treatment in the case of incision model, and after nine days in the case of excision and thermal burn wound models, the time needed for re-epithelialization of the wounded skin being much shorter than in other studies [8].

Wound contraction rate

The wound areas were measured at days 1, 2, 3, 6, 9, 12, and 21. The results are listed in Table 2 and are expressed as mean ± standard error mean (SEM).

Table 2 – ***The values of the wound contraction rate***

Experimental groups	Treatment	WCR_day 6 (Mean ± SEM)	WCR_day 9 (Mean ± SEM)
Hyperici herba ointment group	*Hyperici herba* ointment (one application/day)	80.94±0.31	96.56±0.34*
Ointment base group	Ointment base (one application/day)	26.74±1.23	33.79±1.28**
Negative control group	No treatment	5.78±1.79	14.85±1.70

*P=0.0001, when compared to the negative control group and the ointment base; **P=0.0001, when compared to the negative control group.

No important changes regarding the contraction of the wounds took place in the first three days of treatment (as these are the days when inflammatory processes take place). The cellular proliferation starts after day 3, and significant reduction in the wound areas ($p<0.001$) was achieved at days 6 and 9. There can be noticed that the treatment with *Hyperici herba* ointment shows favorable effects even from the 6th day of the experiment, when compared to the group treated with the ointment base (80.94±0.31 *versus* 26.74±1.23) and especially in comparison with the negative control group (not-treated) (80.94± 0.31 *versus* 5.78±1.79). In the 9th day of treatment, the results are clearly positive, for the *Hyperici herba* ointment group the percent of wound closure being of 96.56±0.34 *versus* 33.79±1.28 (the wound closure for the group treated with the ointment base) or *versus* 14.85±1.7 for the not-treated group. In the 12th day of treatment, the re-epithelialization process was completed for the excision wound model.

Period of re-epithelialization

Hundred percent wound closure was seen in the 12th day of treatment with the *Hyperici herba* ointment when compared to the ointment base group (18th day of the experiment) or to the negative control group which took 21 days for the normal healing.

Histopathological results

The histopathological examination of the skin samples prelevated from the affected areas that were treated for 21 days with the *Hyperici herba* ointment revealed the presence of a mature granulation tissue in almost all the depth of the dermis (for the incision and excision wound models), while in the case of the thermal burn wound model, the granulation process took place in one third of the dermis (Figure 2).

Regarding the group treated with the ointment base, edema can be observed in the case of the linear incision wound model, the presence of koilocytes is noticed in the re-epithelialized areas of excision, and important stasis is present in the hypodermis prelevated from the thermal burn (Figure 2).

For the not-treated group (negative control group), the epithelialization process is clearly delayed and the results depend on the experimental wound model: severe congestion is seen in the hypodermis of the incision wound model, foreign-body granuloma is present in the reticular dermis of the excision wound model, and stasis with thickening of the blood vessels is seen in the case of the thermal burn wound model (Figure 2).

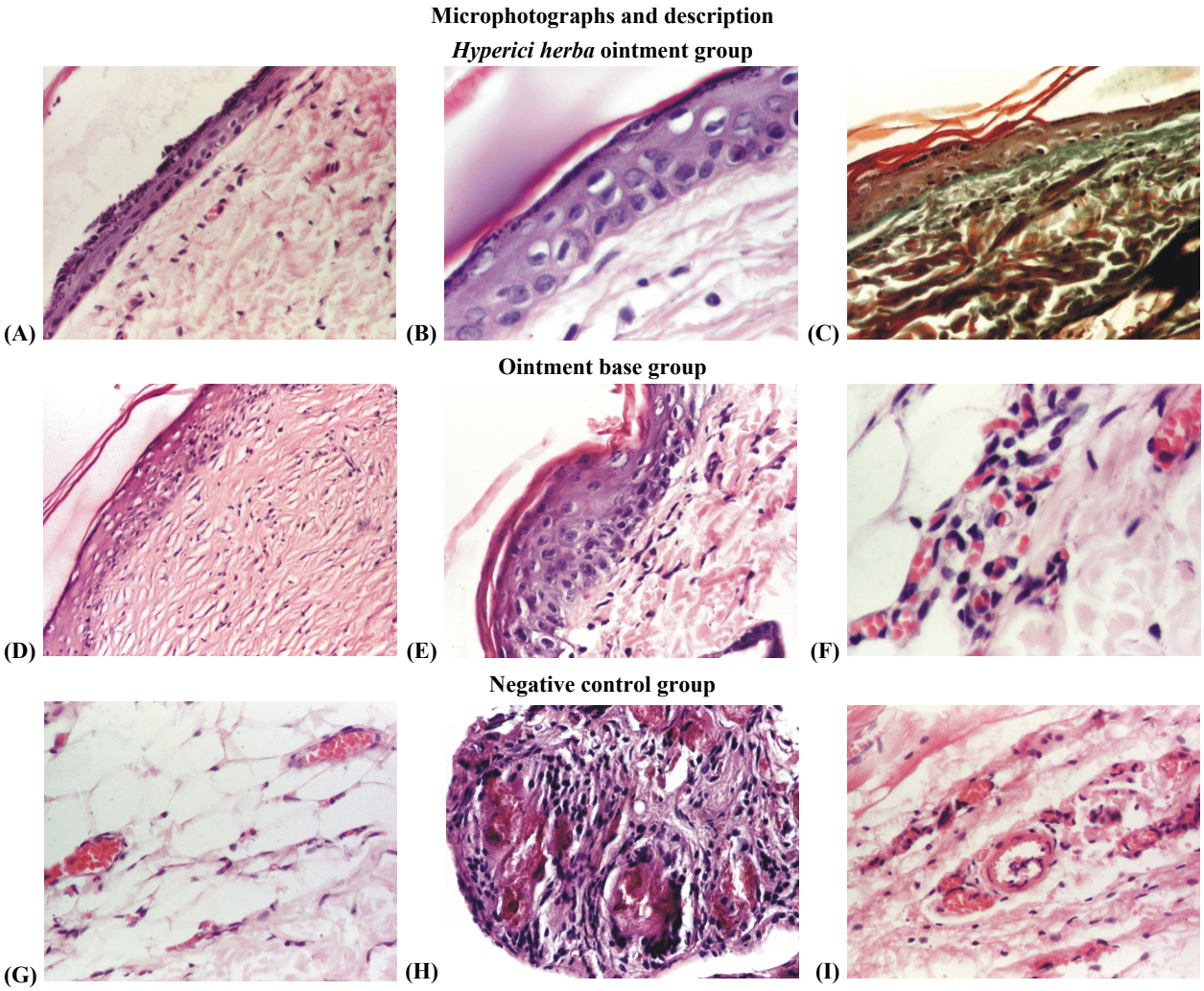

Figure 2 – ***Histopathological evaluation of the tissue samples removed from the healed skin of the Wistar rats at the end of the treatment. Hyperici herba ointment group: (A) Regenerated rectilinear epidermis (incision, HE staining, ×200); (B) Regenerated epithelium (excision, HE staining, ×400); (C) Normal aspect of the collagen in the dermis (thermal burn, Sz staining, ×200). Ointment base group: (D) Epidermis and dermis – collagenization and edema (incision, HE staining, ×100); (E) Epidermis with koilocytes and dermis (excision, HE staining, ×200); (F) Stasis in the hypodermis – detail (thermal burn, HE staining, ×400). Negative control group: (G) Severe congestion in the hypodermis (incision, HE staining, ×200); (H) Foreign body granuloma in the reticular dermis (excision, HE staining, ×200); (I) Stasis in the hypodermis, blood vessel with thickened walls (thermal burn, HE staining, ×200).***

Discussion

The optimal wound healing consists of minimizing tissue damage and providing adequate tissue perfusion and oxygenation, proper nutrition and moist wound healing environment in order to restore the anatomical continuity and function of the affected areas [2]. Wound healing involves continuous cell–cell and cell–matrix interactions that allow the process to proceed in three phases: inflammation (0–3 days, consisting of the establishment of homeostasis and inflammation), cellular proliferation (3–12 days, consisting of granulation, contraction and epithelialization) and remodeling (that last from three to six months, which ultimately determines the strength and appearance of the healed tissue) [9–11]. These phases overlap and ideally a plant-based remedy should affect at least two different processes before it can be said to have some scientific support for its traditional use [3, 12].

The total extract of the aerial parts of St. John's wort improve the healing of the skin injuries by its anti-bacterial, antioxidant, and anti-inflammatory effects.

Wounds provide an environment for the growth of microorganisms [13]. An infected wound is less likely to heal, thus removal and prevention of further infection is a key to rapid and effective wound healing [3]. Infected wounds attract high levels of phagocytic cells, which release reactive oxygen species in an attempt to fight infection; however, these molecules can damage the host cells and delay the healing process [14]. Hyperforin from the *Hyperici herba* extracts, with a chemical structure related to that of the antibacterial keto-enols from the common hop cones, shows antibacterial properties against Gram-positive bacteria (*Staphylococcus aureus*, *Corynebacterium diphtheriae*), this effect being sustained by the presence of tannin, hypericin and essential oil [15].

Although the anti-inflammatory effect of the *Hypericum* extracts was attributed mainly to the inhibitory action of quercetin upon the signal transduction pathway, recent experiments reveal an important role of hyperforin, demonstrating an inhibitory effect upon the lymphocyte reaction at the level of the epidermal cells and upon the

T-lymphocyte proliferation [16]. Hyperforin also interferes with prostanoid generation in biological systems, particularly with key enzymes participating in prostaglandin (PG) E2 biosynthesis, *i.e.*, cyclooxygenases (COX)-1/2 and microsomal PGE2 synthase (mPGES)-1 which play key roles in inflammation and tumorigenesis [17]. On the other hand, hyperforin is one of the natural compounds with a strong inhibitory effect upon cyclooxygenase-1 (COX-1) and lipoxygenase-5 (LOX-5) [18]. This dual mechanism offers the rational basis for the traditional use of St. John's wort in inflammatory dermal disorders. Recent studies demonstrate that hyperforin may interfere with other inflammatory responses of the leukocytes, including the marked inhibition of the reactive oxygen species and release of elastase. These effects seem to be the result of the implications of hyperforin in the G protein-signaling cascade [19].

Burn injuries involve stimulation of intravascular neutrophils and initiate systemic inflammatory reactions by producing toxins such as reactive oxygen species (ROS) almost in every tissue [20, 21]. Lipid peroxide is thought to be one of the most harmful substances produced in burn injuries [22, 23]. A strong connection has been demonstrated to exist between the quantity of lipid peroxidation and the degree of burn complications such as remote organ damage and shock [24, 25]. A primary effect of lipid peroxidation is decreased membrane fluidity, which alters membrane properties and can significantly disrupt membrane-bound proteins [26]. The mechanism of this event is the deformation of cell membrane phospholipids by oxidizing radicals. Oxidative damage of DNA causes formation of adducts of base and sugar groups, single- and double-strand breaks in the backbone, and cross-links to other molecules. Protein damage includes the oxidation of sulfhydryl groups, reduction of disulfides, oxidative adduction of amino acid residues close to metal-binding sites *via* metal-catalyzed oxidation, reactions with aldehydes, protein–protein crosslinking, and peptide fragmentation [27, 28].

Nitric oxide (NO) released by activated macrophages after burn greatly enhances the oxidative stress [29]. Although many immune cells are able to synthesize NO, including natural killer cells, mast cells, phagocytes as well as Th1-type cells [30, 31], macrophages in tissues such as skin represent the main producers of this oxidative mediator after activation [32]. NO, which represents an important mediator of immunosuppression following burn injury, could be responsible for the inhibition of the proliferative response [33]. NO acts directly to inhibit T-cell activity, thus participating in the development of immunosuppression [34–36].

Burn significantly alters levels of cytokines. The cytokines produced after burn such as interleukin-1 (IL-1) and endotoxin activate nuclear factor kappa B (NF-KB), which induces the synthesis of inducible nitric oxide synthase (iNOS) which further produces large amounts of NO and under conditions of substrate or cofactor limitation, may also synthesize superoxide ($O_2\bullet^-$) [37]. NO becomes a potential pro-inflammatory and cytotoxic factor by reacting with $O_2\bullet^-$ to form the toxic product peroxynitrite ($ONOO^-$) [38]. $ONOO^-$ can oxidize/nitrate other molecules or decay and produce even more damaging species, such as the •OH [39, 40]. Reactive nitrogen species (RNS), such as NO, react with guanine to yield the deaminated compound [41, 42].

The degree of novelty brought by our study consists in the method of preparation of the ointment, using a new ointment base (made up of equal amounts of petrolatum and lanolin) and the total extract of *Hypericum perforatum* (made up of both oil and hydroalcoholic extracts). The method of preparation aimed to extract from the aerial parts of *Hypericum perforatum* all the active principles (having a hydrophobic or hydrophilic character), mainly hyperforin, considered to be the main component responsible for the therapeutic effects of the plant.

The extraction step was preferred to the synthesis of hyperforin, as this compound has a unique molecular architecture [43]. Despite its relatively small size, the structure constitutes a thorny synthetic challenge and remains to this day defiant to chemical synthesis [44, 45]. It contains asymmetric vicinal quaternary centers and a densely functionalized tetracarbonyl array. Its prenylated bicyclo[3.3.1]nonanone core is conserved among a number of other acylphloroglucinol derivatives. Synthetic routes to such polycyclic polyprenylated acylphloroglucinols have been developed [46]. Recently, a novel synthetic sequence to polyfunctional, bridged medium-sized rings from simple cyclic ketones has been reported [44]. To date, however, no total synthesis has been described for any of the more than 50 members of this class of substances.

The wound healing process is evident in all the three types of dermal affection: incision, excision, and thermal burn. Regarding the incision, the clinical result consists in the formation of a mature, slender, pliable scar in comparison with the negative control group, which shows a hypertrophic, rigid scar. It is worth mentioning the positive effect of the *Hyperici herba* ointment upon the rate of wound closure, thus suggesting that St. John's wort contains active principles that act synergically in the wound contraction process (one of the most powerful phenomena in the human body).

Maybe the most important observation is regarding the effect of *Hyperici herba* ointment upon the thermal lesion. Besides this effect, the method of treatment of the thermal burn is a premiere, as it is known the fact that thermal injuries are treated first of all by the excision of the affected tissue area, and then by the classical local/systemic procedure. In the present experiment, we have started from the premise that the formed scab is a solution of protection of the organism against the aggressive agent (high temperature in this case). Thus, we have applied the topical treatment keeping the scab. The ointment containing the total extract of *Hypericum perforatum* maintained the moisture degree at the level of the lesion, thus facilitating the penetration of the active principles through the affected skin. The clinical evaluation revealed in the first three days of treatment a perilesional inflammatory infiltrate that started to decrease in the 4th day. Samples of the affected areas were prelevated along the treatment period with a biopsy punch and studied by electronic microscopy, revealing the benefic result upon the regeneration epithelium. Following these results, we assume that the healing process

unrolled as follows: after the favorable effect exerted by the ointment upon the decrease of the inflammatory infiltrate, the healthy perilesional cells migrated towards the adjacent lesional areas, thus leading to the regeneration of the epithelium beneath the scab. As the regeneration process advanced, the healthy tissue pushed the scab away, finally favoring the debridement process. Following the debridement of the scab, the beneath tissue appeared to be newly regenerated, with a specific color, and gradually became mature.

Another advantage of the tested ointment consists in the reduced diameter of the particles (75% of the particles have a diameter of 249 nm determined through the laser diffraction technique) and a good distribution, thus leading to a superior penetration of the active principles through the skin.

Furthermore, the positive effect of the ointment resulted into a very good cosmetic appearance of the affected skin areas, thus recommending the *Hyperici herba* ointment in the treatment of burns that affect a small surface of the skin.

The histopathological results also certify the favorable implication of the tested ointment in the wound healing process, with the regeneration of the epithelium and the normal disposal of the collagen fibers. Furthermore, we can sustain that the ointment containing the total extract of *Hypericum perforatum* reduced the edema at the level of epidermis and dermis and the congestion degree in the hypodermis in the case of lesion with loss of continuity. Moreover, the novel tested ointment had an inhibitory effect upon the stasis in the hypodermis in the case of thermal burn wound.

Conclusions

The clinical and histopathological results, along with the wound contraction rate and period of epithelialization, demonstrate the wound-healing effect of the novel St. John's wort ointment in linear incisions, circular excisions and thermal burns. The results are clearly superior to those cited in other studies.

Acknowledgments

This paper was supported by the project PERFORM-ERA "Postdoctoral Performance for Integration in the European Research Area" (ID-57649), financed by the European Social Fund and the Romanian Government.

References

[1] Schreml S, Szeimies RM, Prantl L, Landthaler M, Babilas P, *Wound healing in the 21st century*, J Am Acad Dermatol, 2010, 63(5):866–881.

[2] Pierce GF, Mustoe TA, *Pharmacologic enhancement of wound healing*, Annu Rev Med, 1995, 46:467–481.

[3] Adetutu A, Morgan WA, Corcoran O, *Ethnopharmacological survey and in vitro evaluation of wound-healing plants used in South-western Nigeria*, J Ethnopharmacol, 2011, 137(1):50–56.

[4] Shenoy RR, Sudheendra AT, Nayak PG, Paul P, Kutty NG, Rao CM, *Normal and delayed wound healing is improved by sesamol, an active constituent of Sesamum indicum (L.) in albino rats*, J Ethnopharmacol, 2011, 133(2):608–612.

[5] Sanwal R, Chaudhary AK, *Wound healing and antimicrobial potential of Carissa spinarum Linn. in albino mice*, J Ethnopharmacol, 2011, 135(3):792–796.

[6] Süntar IP, Akkol EK, Yilmazer D, Baykal T, Kirmizibekmez H, Alper M, Yeşilada E, *Investigations on the in vivo wound healing potential of Hypericum perforatum L.,* J Ethnopharmacol, 2010, 127(2):468–477.

[7] de Mesquita CJG, Leite JAD, Fechine FV, Rocha JLC, Leite JGS, Leite Filho JAD, Barbosa Filho RA, *Effect of imiquimod on partial-thickness burns*, Burns, 2010, 36(1): 97–108.

[8] Akkol EK, Süntar I, Keles H, Yeşilada E, *The potential role of female flowers inflorescence of Typha domingensis Pers. in wound management*, J Ethnopharmacol, 2011, 133(3): 1027–1032.

[9] Clark RAF, Wound repair: overview and general considerations. In: Clark RAF (ed), *The molecular and cellular biology of wound repair*, 2nd edition, Plenum Press, New York, 1996, 3–50.

[10] Martin A, *The use of antioxidants in healing*, Dermatol Surg, 1996, 22(2):156–160.

[11] Kumar B, Vijayakumar M, Govindarajan R, Pushpangadan P, *Ethnopharmacological approaches to wound healing – exploring medicinal plants of India*, J Ethnopharmacol, 2007, 114(2):103–113.

[12] Houghton PJ, Hylands PJ, Mensah AY, Hensel A, Deters AM, *In vitro tests and ethnopharmacological investigations: wound healing as an example*, J Ethnopharmacol, 2005, 100(1–2): 100–107.

[13] Somboonwong J, Thanamittramanee S, Jariyapongskul A, Patumraj S, *Therapeutic effects of Aloe vera on cutaneous microcirculation and wound healing in second degree burn model in rats*, J Med Assoc Thai, 2000, 83(4):417–425.

[14] Altomare E, Vendemiale G, Grattagliano I, Angelini P, Micelli-Ferrari T, Cardia L, *Human diabetic cataract: role of lipid peroxidation*, Diabetes Metab, 1995, 21(3):173–179.

[15] Istudor V, *Farmacognozie. Fitochimie. Fitoterapie. Vol. I: Oze, ozide şi lipide*, Ed. Medicală, Bucureşti, 1998, 234.

[16] Schempp CM, Winghofer B, Lüdtke R, Simon-Haarhaus B, Schöpf E, Simon JC, *Topical application of St. John's wort (Hypericum perforatum L.) and of its metabolite hyperforin inhibits the allostimulatory capacity of epidermal cells*, Br J Dermatol, 2000, 142(5):979–984.

[17] Koeberle A, Rossi A, Bauer J, Dehm F, Verotta L, Northoff H, Sautebin L, Werz O, *Hyperforin, an anti-inflammatory constituent from St. John's Wort, inhibits microsomal prostaglandin E(2) synthase-1 and suppresses prostaglandin E(2) formation in vivo*, Front Pharmacol, 2011, 2:7.

[18] Albert D, Zündorf I, Dingermann T, Müller WE, Steinhilber D, Werz O, *Hyperforin is a dual inhibitor of cyclooxygenase-1 and 5-lipoxygenase*, Biochem Pharmacol, 2002, 64(12):1767–1775.

[19] Feisst C, Werz O, *Suppression of receptor-mediated Ca2+ mobilization and functional leukocyte responses by hyperforin*, Biochem Pharmacol, 2004, 67(8):1531–1539.

[20] Cetinkale O, Konukoğlu D, Senel O, Kemerli GD, Yazar S, *Modulating the functions of neutrophils and lipid peroxidation by FK506 in a rat model of thermal injury*, Burns, 1999, 25(2):105–112.

[21] Yeh SL, Shang HF, Lin MT, Yeh CL, Chen WJ, *Effects of dietary glutamine on antioxidant enzyme activity and immune response in burned mice*, Nutrition, 2003, 19(10):880–885.

[22] Hoşnuter M, Gürel A, Babucçu O, Armutcu F, Kargi E, Işikdemir A, *The effect of CAPE on lipid peroxidation and nitric oxide levels in the plasma of rats following thermal injury*, Burns, 2004, 30(2):121–125.

[23] Saitoh D, Okada Y, Ookawara T, Yamashita H, Takahara T, Ishihara S, Ohno H, Mimura K, *Prevention of ongoing lipid peroxidation by wound excision and superoxide dismutase treatment in the burned rat*, Am J Emerg Med, 1994, 12(2): 142–146.

[24] Sáez JC, Ward PH, Günther B, Vivaldi E, *Superoxide radical involvement in the pathogenesis of burn shock*, Circ Shock, 1984, 12(4):229–239.

[25] Oldham KT, Guice KS, Till GO, Ward PA, *Activation of complement by hydroxyl radical in thermal injury*, Surgery, 1988, 104(2):272–279.

[26] Trombly R, Tappel A, *Fractionation and analysis of fluorescent products of lipid peroxidation*, Lipids, 1975, 10(8):441–447.

[27] Stadtman ER, Oliver CN, *Metal-catalyzed oxidation of proteins. Physiological consequences*, J Biol Chem, 1991, 266(4):2005–2008.

[28] Starke-Reed PE, Oliver CN, *Protein oxidation and proteolysis during aging and oxidative stress*, Arch Biochem Biophys, 1989, 275(2):559–567.
[29] Lindblom L, Cassuto J, Yregård L, Mattsson U, Tarnow P, Sinclair R, *Importance of nitric oxide in the regulation of burn oedema, proteinuria and urine output*, Burns, 2000, 26(1): 13–17.
[30] Bogdan C, *Nitric oxide and the immune response*, Nat Immunol, 2001, 2(10):907–916.
[31] Kendall HK, Marshall RI, Bartold PM, *Nitric oxide and tissue destruction*, Oral Dis, 2001, 7(1):2–10.
[32] Masson I, Mathieu J, Nolland XB, De Sousa M, Chanaud B, Strzalko S, Chancerelle Y, Kergonou JF, Giroud JP, Florentin I, *Role of nitric oxide in depressed lympho-proliferative responses and altered cytokine production following thermal injury in rats*, Cell Immunol, 1998, 186(2): 121–132.
[33] Mills CD, *Molecular basis of "suppressor" macrophages. Arginine metabolism via the nitric oxide synthetase pathway*, J Immunol, 1991, 146(8):2719–2723.
[34] Schwacha MG, Samy TS, Catania RA, Chaudry IH, *Thermal injury alters macrophage responses to prostaglandin E2: contribution to the enhancement of inducible nitric oxide synthase activity*, J Leukoc Biol, 1998, 64(6):740–746.
[35] Stein CS, Strejan GH, *Rat splenocytes inhibit antigen-specific lymphocyte proliferation through a reactive nitrogen intermediate (RNI)-dependent mechanism and exhibit increased RNI production in response to IFN-gamma*, Cell Immunol, 1993, 150(2):281–297.
[36] Huang FP, Niedbala W, Wei XQ, Xu D, Feng GJ, Robinson JH, Lam C, Liew FY, *Nitric oxide regulates Th1 cell development through the inhibition of IL-12 synthesis by macrophages*, Eur J Immunol, 1998, 28(12):4062–4070.
[37] Xia Y, Roman LJ, Masters BS, Zweier JL, *Inducible nitric-oxide synthase generates superoxide from the reductase domain*, J Biol Chem, 1998, 273(35):22635–22639.
[38] Szabó C, Salzman AL, Ischiropoulos H, *Endotoxin triggers the expression of an inducible isoform of nitric oxide synthase and the formation of peroxynitrite in the rat aorta in vivo*, FEBS Lett, 1995, 363(3):235–238.
[39] Espey MG, Miranda KM, Pluta RM, Wink DA, *Nitrosative capacity of macrophages is dependent on nitric-oxide synthase induction signals*, J Biol Chem, 2000, 275(15):11341–11347.
[40] Mogoşanu GD, Popescu FC, Busuioc CJ, Pârvănescu H, Lascăr I, *Natural products locally modulators of the cellular response: therapeutic perspectives in skin burns*, Rom J Morphol Embryol, 2012, 53(2):249–262.
[41] Grishko VI, Druzhyna N, LeDoux SP, Wilson GL, *Nitric oxide-induced damage to mtDNA and its subsequent repair*, Nucl Acids Res, 1999, 27(22):4510–4516.
[42] Parihar A, Parihar MS, Milne S, Bhat S, *Oxidative stress and anti-oxidative mobilization in burn injury*, Burns, 2008, 34(1):6–17.
[43] Beerhues L, *Hyperforin*, Phytochemistry, 2006, 67(20): 2201–2207.
[44] Nicolaou KC, Carenzi GEA, Jeso V, *Construction of highly functionalized medium-sized rings: synthesis of hyperforin and perforatumone model systems*, Angew Chem Int Ed Engl, 2005, 44(25):3895–3899.
[45] Kraus GA, Nguyen TH, Jeon I, *Synthesis of the core bicyclic system of hyperforin and nemorosone*, Tetrahedron Lett, 2003, 44(4):659–661.
[46] Ciochina R, Grossman RB, *A new synthetic approach to the polycyclic polyprenylated acylphloroglucinols*, Org Lett, 2003, 5(24):4619–4621.

Corresponding author
Anca Sava, MD, Discipline of Anatomy and Embryology, Faculty of Medicine, "Grigore T. Popa" University of Medicine and Pharmacy, 16 Universităţii Street, 700115 Iassy, Romania; Phone +40744–303 678, Fax +40232–301 633, e-mail: dr_anca_sava@yahoo.com

Received: May 23, 2013

Accepted: December 17, 2013