ORIGINAL PAPER

RJME
Romanian Journal of Morphology & Embryology
http://www.rjme.ro/

CT characters *versus* morphopathological characters in pharyngeal squamous cell carcinoma

ANA MAGDALENA BRATU[1)], IULIA ALECSANDRA SĂLCIANU[1)], DANIEL ALIN CRISTIAN[2)], CONSTANTIN ZAHARIA[3)], GAROFIŢA OLIVIA MATEESCU[4)], MARIUS MATEI[4)], ŞERBAN VIFOR GABRIEL BERTEŞTEANU[5)], GABRIELA LICĂ[6)], ELENA CARMEN NICULESCU[7)]

[1)] *Department of Radiology, Colţea Clinical Hospital, Bucharest, Romania*

[2)] *Department of General Surgery, Colţea Clinical Hospital, Bucharest, Romania; "Carol Davila" University of Medicine and Pharmacy, Bucharest, Romania*

[3)] *Department of Radiology, Colţea Clinical Hospital, Bucharest, Romania; "Carol Davila" University of Medicine and Pharmacy Bucharest, Romania*

[4)] *Department of Histology, University of Medicine and Pharmacy of Craiova, Romania*

[5)] *Department of Otolaryngology, Colţea Clinical Hospital, Bucharest, Romania; "Carol Davila" University of Medicine and Pharmacy, Bucharest, Romania*

[6)] *Department of Pathology, Colţea Clinical Hospital, Bucharest, Romania*

[7)] *Department of Pediatrics, Faculty of Medicine, University of Medicine and Pharmacy of Craiova, Romania*

Abstract

Pharyngeal squamous cell carcinoma is a rare neoplasm, whose incidence increases with age. Computed tomography (CT) imaging is an easy way to explore the pharyngeal region, having the advantage of being able to highlight and characterize the existence of a tumor in this region, and to determine its local extension and lymphatic metastasis. In this group were included a total of 27 patients, who, following the histopathological findings were diagnosed with pharyngeal squamous cell carcinoma and who have previously received a CT scan. CT examination protocol included a native scan and post-intravenous administration of contrast medium, in both the arterial phase and in parenchymal and venous phase. The scan was made with 2 mm thin sections, subsequently were performed coronal and sagittal reconstructions. The examination plan included the thoracic region down to the aperture. The paper tries to establish correlations between the morphological appearance and semiological computed tomography characters of the lesions.

Keywords: computed tomography, squamous cell carcinoma, pharynx, lymphatic metastasis.

Introduction

Squamous cell carcinoma (SCC), though a rare neoplasm, is frequent in otolaryngology. Its localization affects the sinus, nasopahrynx, oropharynx, and hypopharynx areas.

For malignant tumors such as SCC, rapid growth may occur even though there are no previous clinical signs [1]. For this reason, clinical examination must be complemented by radiological examination [2] for the assessment of size, thickness and depth of the tumor [3] as well as the degree of bone tissue invasion [4–6].

Anatomically and topographically, imaging these regions require special technical approaches in terms of patient positioning, section thickness, retro-reconstruction and 2D, eventually 3D reconstruction.

Referring strictly to the pharyngeal region, for diagnostic purpose, a "standard" exploration is performed initially, which requires a computed tomography (CT) acquisition with 2 mm thin sections, subsequently being achieved a coronal and sagittal reconstruction. After locating the lesion, the CT exam is extended in relation to the examined subregion (oropharynx, hypopharynx), to assess the exact locoregional extension of the lesion. It is mandatory for the examination to be performed with intravenous contrast material in at least two phases. The examination is made compulsory with intravenous contrast material in at least two phases [7–10].

Epidemiologically, the pharyngeal squamous cancer affects both sexes in almost equal proportions, with slight preference for males. In terms of age, is seen most commonly in the decade 6 and 7, but it can occur even in children. Between 40 and 60 years, is considered that men have a two-fold risk of developing pharyngeal squamous cell carcinoma than women. Smoking is the major risk factor incriminated, statistics considering that smoking more than 20 years doubles the risk of developing squamous cell cancer. Prolonged exposure to dust and chemicals, such as polycyclic aromatic hydrocarbons, are also considered as major risk factors for pharyngeal squamous cancer [11–14].

The purpose of this study is only comparative evaluation of malignancy characters of a tumor, as detected by an imaging examination in relation to its characteristics pathologically evaluated. It was attempted the detection of similar features between the two methods in order to provide more comprehensive information to the surgeon preoperatively.

The present paper makes a pertinent analysis of the

limits of the method in terms of CT and its role in the diagnosis of pharyngeal SCC.

Patients and Methods

A total of 27 cases of patients were studied, all diagnosed and operated with squamous cancer with pharyngeal location. Of these, one case had a nasopharyngeal cancer, 11 had oropharyngeal cancer, 13 had cancer with hypopharyngeal localization and two had a tumor extending both oro- and hypopharyngeal, making the onset almost impossible.

During the selection of cases, which extended over a period of six months (the first half of 2014), there were used the following selection criteria:

- the patients' age: between 40 and 70 years;
- diagnosis: patients with squamous cell cancer with pharyngeal localization, exophytic shape;
- the stage of the disease: there were selected patients without distant metastases, in order not to complicate the examination protocol, that otherwise required chest X-ray, abdominal ultrasound and/or abdominal CT.

All had undergone preoperative CT scan, native and with intravenous contrast material. The examination was performed on Siemens Emotion Duo equipment with contiguous 2 mm sections and sagittal and coronal MIP reconstructions.

For the nasopharyngeal cancer, the study focused on cavum, the paranasal sinuses and skull base. Considering possible intracranial extension, CT examination was performed, native and with cerebral contrast material, for a possible invasion in the brain.

Brain CT examination protocol consisted of contiguous sections of 3 mm for the posterior fossa region and 5 mm for the rest of the region. The reconstructions were performed with bone window for an accurate assessment of the possible bone invasion.

For sinuses examination, additional paranasal sinuses CT was performed, with the patient in a specific position, with contiguous sections of 2 mm, native and with intravenous contrast material, with reconstruction with bone window, to assess the eventual invasion at this level.

For the oropharyngeal cancer, there were carefully studied the tonsils region, the extension into the larynx, in the extrinsic muscles of the tongue, medial and lateral pterygoids, and also a possible bone invasion in the hard palate, mandible, skull base, and the vascular structures – carotid artery.

For the hypopharyngeal cancer, the pyriform sinuses, prevertebral space, tongue base, the pharyngolaryngeal wall, the glottis region, the thyroid cartilage were carefully examined, CT exploration protocol extending beyond the pharyngoesophageal junction.

The cervical lymph node groups were studied, analyzing the size of any adenopathies, lymph nodes' contours, their structure and how they filled with contrast material.

The imaging examination result was confronted with the operator protocol and the histopathological examination, trying to find correlations between the histopathological stadialization form, size of the tumor, locoregional extension, the degree of lymph node invasion – determined by CT, with the pathological appearance and histopathological characteristics of the tumor.

For the morphological study, we used fragments of pharyngeal tumors harvested during the surgery, fixed in 10% formalin and included in paraffin. For the histopathological diagnosis, we used the classical Hematoxylin–Eosin (HE) staining, and for the differential diagnosis, we used an additional immunohistochemistry technique, by marking the histopathological samples with three antibodies: anti-Ki67 (MIB-1, Ms/Hu/Monoclonal, Dako), for highlighting the proliferative activity of various types of pharyngeal tumors; anti-p53 (DO-7, Ms/Hu/Monoclonal, Dako), for highlighting possible alterations of TP53 gene; anti-34βE12 CK (M0630, Dako) for highlighting the emphasis of cytokeratins with a high molecular weight in the cytoskeleton filaments.

All techniques used in this study are standard procedures approved nationally and internationally, are used routinely in all health facilities.

Results

Of the total of 27 cases, examined in the time interval of the study, there were identified three cases of well differentiated squamous cell carcinoma, 22 cases of intermediate differentiated squamous cell carcinoma and two poorly differentiated squamous cell carcinoma cases.

By localization, the nasopharyngeal squamous cell carcinoma case was a poorly differentiated cancer, the cases with oropharyngeal localization, two were well differentiated and nine intermediate differentiated, from the 13 cases of hypopharyngeal localization, one was well differentiated and 12 intermediate differentiated and in the two cases with oro-hypopharyngeal extension, one was a poorly differentiated cancer (Table 1).

Table 1 – ***Distribution of histological pharyngeal squamous cell carcinoma cases***

Histological type	Squamous cell carcinoma localization			
	Naso-pharynx	*Oro-pharynx*	*Hypo-pharynx*	*Oro-hypopharynx*
Well differentiated	0	2	1	0
Moderately differentiated	0	9	12	1
Poorly differentiated	1	0	0	1

All the studied cases were exophytic neoplasms, protruding into the lumen of the pharynx.

The images show the histological differentiations between the three types of squamous cancer, differenttiation that cannot be appreciated by any imagistic test used in the diagnosis and staging of malignant tumors.

Spinocellular epidermoid carcinomas appeared as being formed of cells placed as islands or cordons, quite variable in shape and size, resembling the epithelial cells in the spinous stratum. The tissular structure was completely altered, strongly contrasting with the stratified Malpighian epithelial cells, without any keratinization. Generally, tumoral cells presented important shape and size variations, giving the tumoral parenchyma a pleomorphic aspect. The main characteristic of tumoral cells was atypia, the neoplastic cells presenting nuclei of various sizes, much larger than in normal epithelial cells, thus determining the reverse process of nucleus/cytoplasm ratio in favor of the nucleus. The cell nuclei presented as either hyperchromic, with an irregular

shape, with invaginations or nuclear buddings, with an uneven chromatin, either under the nuclear membrane or as clusters, which led to a heterogeneous coloring of the nucleus. Other times, the nuclei presented with large sizes, with a monstrous aspect. The nucleoli most often presented quite large, multiple, well differentiated, either centrally located or in the immediate proximity of the nuclear membrane (Figures 1–3).

For highlighting the cellular proliferation processes in the three types of squamous cell pharyngeal carcinomas (well, moderately or poorly differentiated), we used the anti-Ki67 antibody. As it may be observed from our images, the immunohistochemical reaction was a moderate or intense one in all types of pharyngeal carcinomas, indicating high proliferation ability (Figures 4–6).

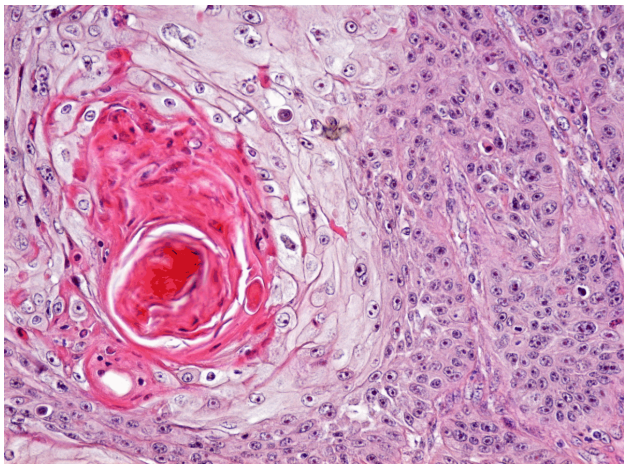

Figure 1 – ***Well-differentiated squamous cell carcinoma keratinizing-type. HE staining, ×200.***

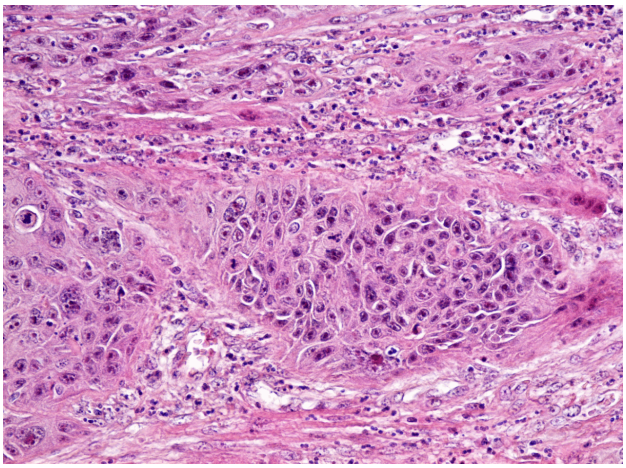

Figure 2 – ***Moderately differentiated squamous cell carcinoma. HE staining, ×200.***

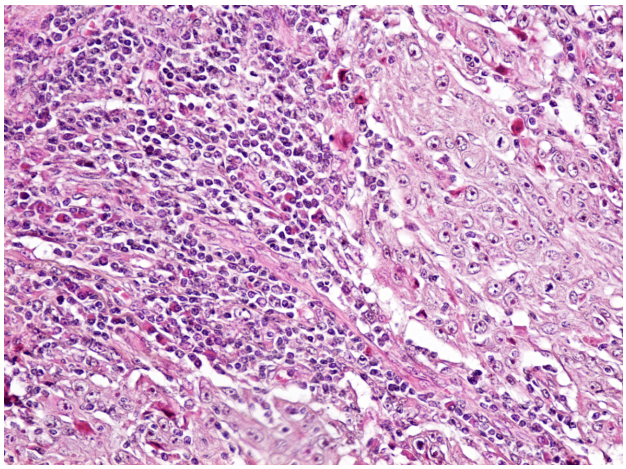

Figure 3 – ***Squamous cell carcinoma poorly differentiated. HE staining, ×200.***

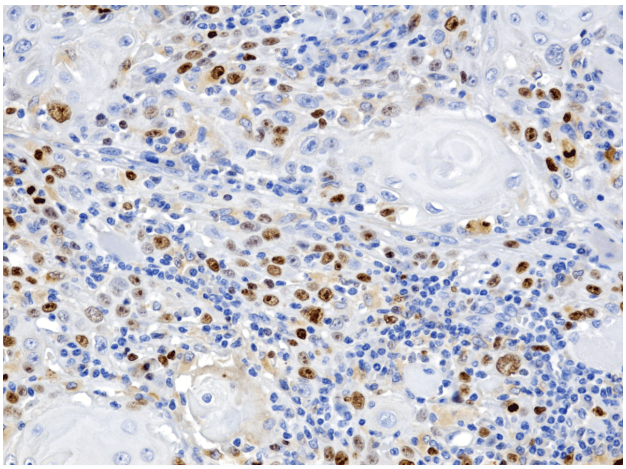

Figure 4 – ***Microscopic image of a well differentiated squamous cell carcinoma, with a moderate reaction to anti-Ki67. Anti-Ki67 antibody immunomarking, ×200.***

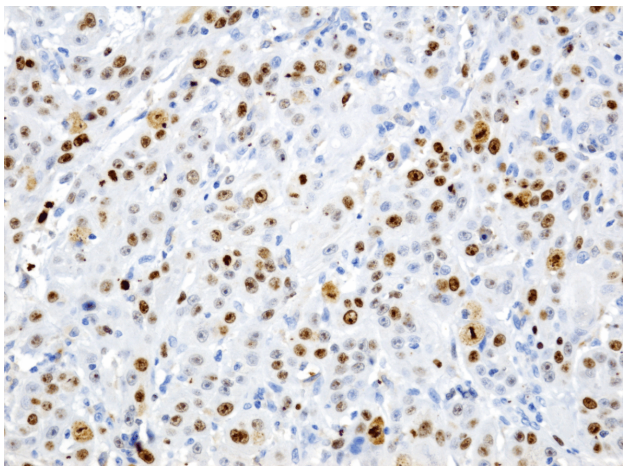

Figure 5 – ***Moderately differentiated squamous cell carcinoma, with an intense reaction to anti-Ki67. Anti-Ki67 antibody immunomarking, ×200.***

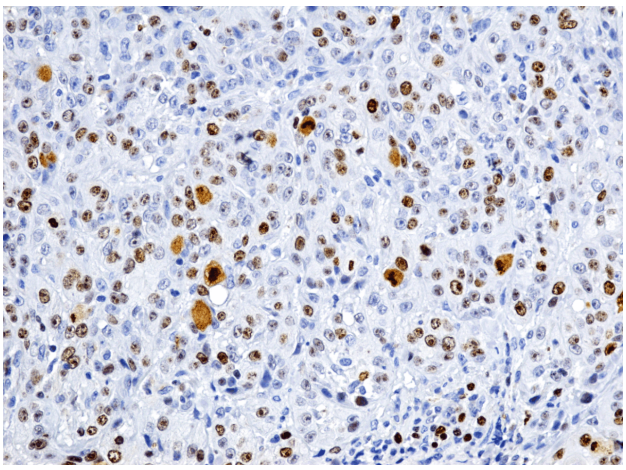

Figure 6 – ***Poorly differentiated squamous cell carcinoma, with an intense reaction to anti-Ki67. Anti-Ki67 antibody immunomarking, ×200.***

The TP53 gene, a tumor suppressor gene, codifies the p53 protein synthesis, also known as the "genome guardian", due to its part played in preserving the genome stability. By investigating the immunohistochemical reaction to the anti-p53 antibody, there could be observed that some tumors presented a mild reaction (Figures 7–10), irrespective of the tumor differentiation degree. Our data show that, in almost all cases of pharyngeal carcinoma, there arised genetic mutations, their intensity varying from one case to another.

The highlighting of epithelial cells characteristics and the differentiation from mesenchymal cells was performed by using the anti-34βE12 cytokeratin antibody. The most intense reaction was obtained in the well-differentiated squamous cell pharyngeal carcinomas and it diminished together with the reduction of tumor differentiation degree (Figures 11–13).

The only possible evaluation criterion would remain the degree of contrast material enhancement to the tumor mass, but even this is directly related to the tumor microvasculature, not being necessarily related to the degree of mitotic division.

Analyzing the dimensional criterion shown by computed tomography, the distribution of the 27 cases was the following (Table 2).

Table 2 – ***Analysis of dimensional criteria in relation to tumor histology and tumor location***

Histological type	Squamous cell carcinoma localization (No. of cases)											
	Nasopharynx			*Oropharynx*			*Hypopharynx*			*Oro-hypopharynx*		
	<2 cm	*2–4 cm*	*>4 cm*	*<2 cm*	*2–4 cm*	*>4 cm*	*<2 cm*	*2–4 cm*	*>4 cm*	*<2 cm*	*2–4 cm*	*>4 cm*
Well differentiated	-	-	-	1	1	-	-	1	-	-	-	-
Moderately differentiated	-	-	-	-	7	2	-	10	2	-	-	1
Poorly differentiated	-	-	1	-	-	-	-	-	-	-	-	1

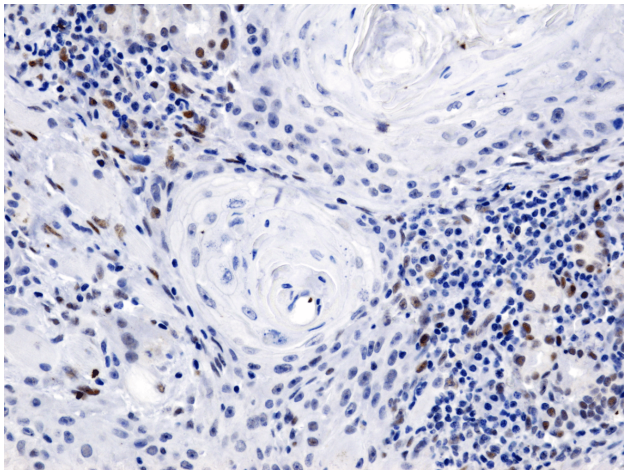

Figure 7 – ***Microscopic image of a well differentiated squamous cell carcinoma, with a poor reaction to anti-p53. Anti-p53 antibody immunomarking, ×200.***

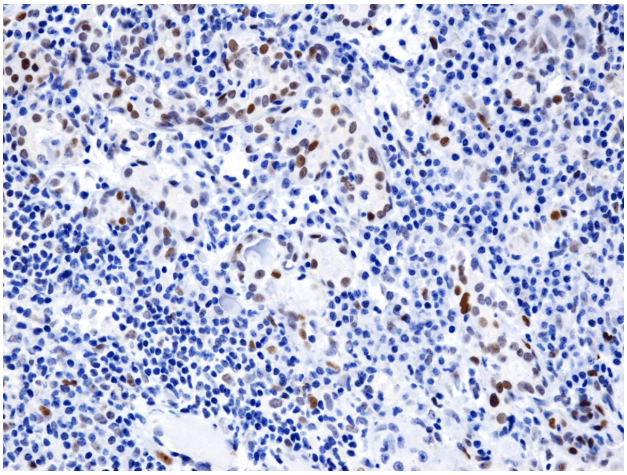

Figure 8 – ***Moderately differentiated squamous cell carcinoma, with a poor reaction to anti-p53. Anti-p53 antibody immunomarking, ×100.***

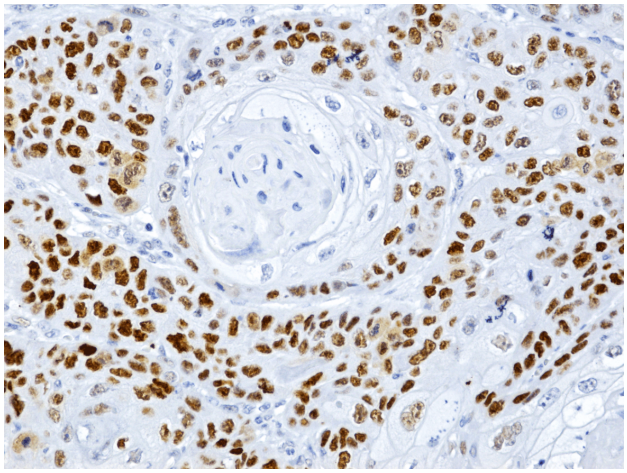

Figure 9 – ***Well-differentiated squamous cell carcinoma, with an intense reaction to anti-p53. Anti-p53 antibody immunomarking, ×200.***

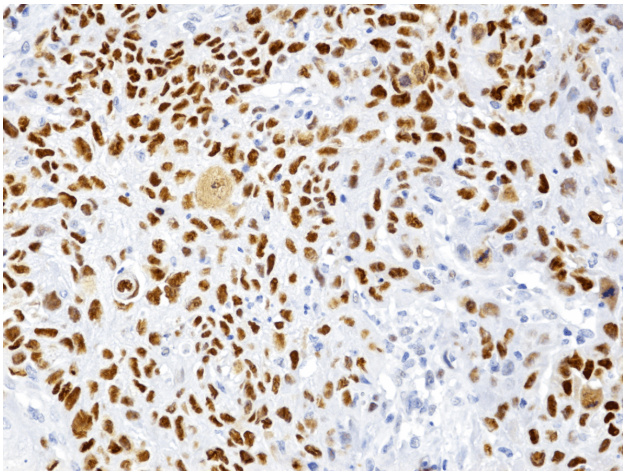

Figure 10 – ***Moderately differentiated squamous cell carcinoma, with an intense reaction to anti-p53. Anti-p53 antibody immunomarking, ×200.***

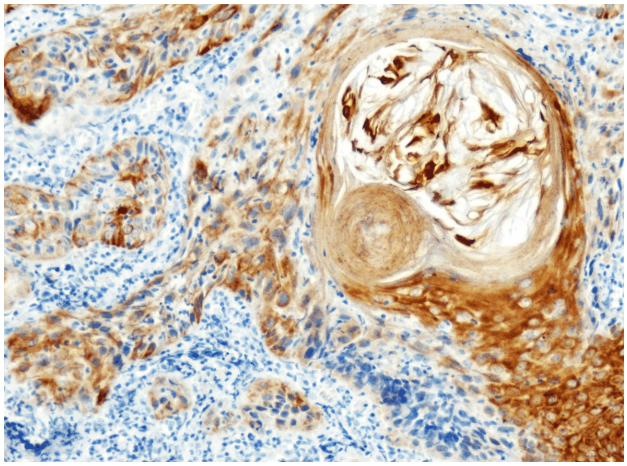

Figure 11 – ***Image of well-differentiated squamous cell carcinoma, with an intense reaction to anti-34βE12 cytokeratin. Anti-34βE12 cytokeratin antibody immunomarking, ×100.***

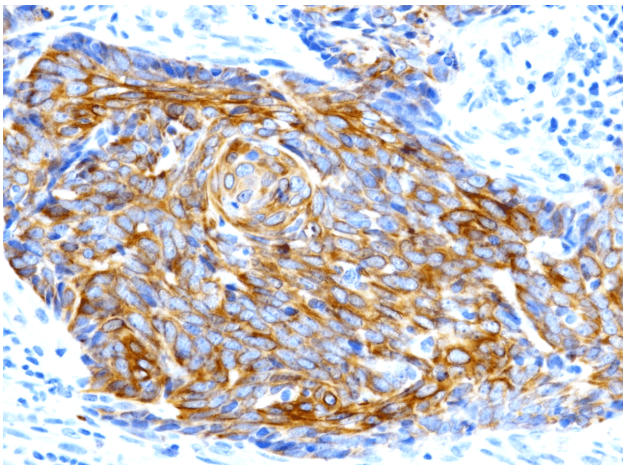

Figure 12 – ***Island of moderately differentiated squamous cell carcinoma, with moderate reaction to anti-34βE12 cytokeratin. Anti-34βE12 cytokeratin antibody immunomarking, ×200.***

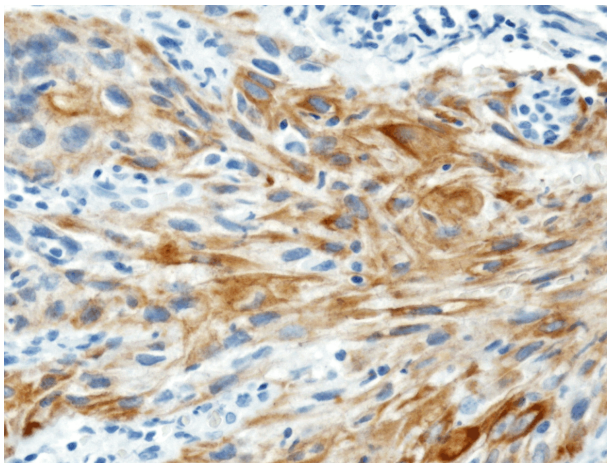

Figure 13 – ***Poorly differentiated squamous cell carcinoma, with a poor reaction to anti-34βE12 cytokeratin. Anti-34βE12 cytokeratin antibody immunomarking, ×400.***

Given the anatomical adjacency relations of the pharynx, the degree of invasion of the tumor in the three types of squamous cell carcinoma was made in relation to each type of localization of the squamous cell carcinoma.

Therefore, in the case of nasopharyngeal squamous cell carcinoma, it was taken into account that the extension can be made to nearby soft tissue, the bones of nasal cavity, the paranasal sinuses, the orbit, the skull base, the oropharynx and content of the neurocranium.

In the only case of nasopharyngeal squamous cell carcinoma, was found that the tumor had invaded the ethmoid region, complying the wall of the orbit and the skull base, but completely abolishing the cavum. At the same time, the tumor had come into direct contact with the carotid artery, which it partially invaded, determining disturbances in its flow (Figure 14).

Tumor extension of the oropharyngeal squamous cell carcinoma, uses in T staging the centimetric dimensional criteria, but at the same time, for the T4 stage, the extension in the bone tissue, muscle and skin must be analyzed. Given these criteria, the distribution of the analyzed cases was the following (Table 3, Figure 15).

Table 3 – ***Analysis of tumor extension criteria in relation to histological type of oropharyngeal squamous cell carcinoma***

Histological type	Tumor extension (No. of cases)			
	Pharyngeal wall	*Para-pharyngeal spaces*	*Muscle structures*	*Vascular structures*
Well differentiated	1	1	-	-
Moderately differentiated	-	9	7	1

Muscle extension of the tumor is computed tomography detectable both directly and by using the imaging term "deletion of demarcation interface with the muscle structure", without being able to specify exactly whether or not the actual invasion exists (Figure 16). From this point of view the histopathological examination correctly executed in the targeted area, brings superior information compared to the imaging exam.

Using the same extension criteria of the tumor with hypopharyngeal localization, the distribution of the analyzed cases was the following (Table 4, Figures 17 and 18).

Structurally, all studied tumors had both in native computed tomography and intravenous contrast material computed tomography scans a heterogeneous structure.

Table 4 – ***Analysis of tumor extension criteria in relation to histological type of hypopharyngeal squamous cell carcinoma***

Histological type	Tumor extension (No. of cases)				
	Laryngeal extension	*Parapharyngeal spaces*	*Muscle and vascular structures*	*Piriform sinus + vocal cords*	*Esophagus*
Well differentiated	1	-	-	-	-
Moderately differentiated	6	5	7	2	1

Figure 14 – ***Cerebral computer tomography with contrast media – poorly differentiated nasopharyngeal squamous cell carcinoma with ethmoidal extension.***

Figure 15 – ***Cervical computer tomography with contrast media – moderately differentiated oropharyngeal squamous cell carcinoma with medial pterygoid muscle extension.***

Figure 16 – ***Cervical computer tomography with contrast media – moderately differentiated oropharyngeal squamous cell carcinoma with tonsils and palato-pharyngeal muscle extension.***

Figure 17 – ***Cervical computer tomography with contrast media – moderately differentiated hypopharyngeal squamous cell carcinoma with piriform sinus and cricoid cartilage invasion.***

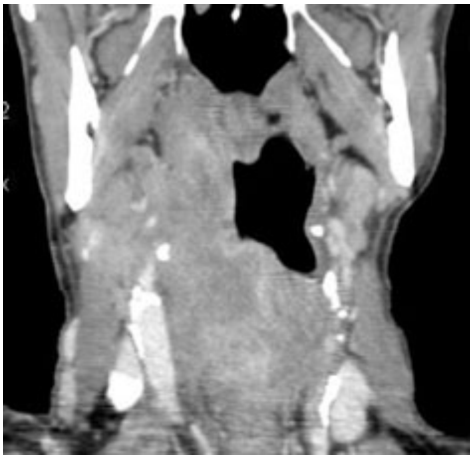

Figure 18 – ***Cervical computer tomography with contrast media – MPR reconstruction – moderately differenttiated hypopharyngeal squamous cell carcinoma with laryngo-esophageal invasion.***

On the native computed tomography, well differentiated squamous cell carcinoma were iso- and hypodense compared to adjacency structures. Intermediate differentiated squamous cell carcinomas were mostly hypodense, the ones with orohypopharyngeal localization featuring necrosis areas.

Intratumoral necrosis was seen in both cases of poorly differentiated squamous cell carcinoma.

The intensity of the contrast medium enhancement in all cases of squamous cell carcinoma was heterogeneous, on the well-differentiated ones being able to highlight areas with contrast medium enhancement lower than most of the tumor.

On intermediate and poorly differentiated squamous cell carcinoma, the intensity of the contrast medium enhancement was mostly higher than normal structures.

Lymph node extension of squamous cell carcinoma is a mandatory analysis for diagnosis and computed tomography staging of cases of malignant tumors.

Analyzing the 27 cases of squamous cell carcinoma with pharyngeal localization, the results of this evaluation criterion were the following (Table 5, Figure 19).

In terms of dimensional criteria of lymph nodes in SCC, the analysis of the studied cases revealed the following results (Table 6).

Structurally, it was found that all adenopathies with sizes under 3 cm, had intense, homogenous contrast medium enhancement, the presence of necrosis areas being found on all adenopathies with sizes over 6 cm, but also on adenopathies with sizes between 3 and 6 cm (Figure 20).

A case of lymphadenopathy over 6 cm presented ganglion capsule breakage.

The presence of peritumoral inflammatory changes has been found in all cases of poorly differentiated squamous cell carcinoma and in six cases of intermediate differentiated squamous cell carcinoma.

Table 5 – ***The presence of adenopathies in relation to histological structure in pharyngeal squamous cell carcinoma***

Histological type	Adenopathies (No. of cases)			
	Nasopharyngeal SCC	*Oropharyngeal SCC*	*Hypopharyngeal SCC*	*Oro-hypopharyngeal SCC*
Well differentiated	0	1	1	0
Moderately differentiated	0	9	12	1
Poorly differentiated	1	0	0	1

Table 6 – *Analysis dimensional criteria of lymph nodes in relation to tumor histology and tumor localization*

Histological type	Squamous cell carcinoma localization (No. of cases)											
	Nasopharynx			*Oropharynx*			*Hypopharynx*			*Oro-hypopharynx*		
	No lymph nodes	*<6 cm*	*>6 cm*	*No lymph nodes*	*3–6 cm*	*>6 cm*	*<3 cm*	*3–6 cm*	*>6 cm*	*<3 cm*	*3–6 cm*	*>6 cm*
Well differentiated	-	-	-	1	1	-	1	-	-	-	-	-
Moderately differentiated	-	-	-	-	7	1	2	8	2	-	1	-
Poorly differentiated	-	-	1	-	-	-	-	-	-	-	-	1

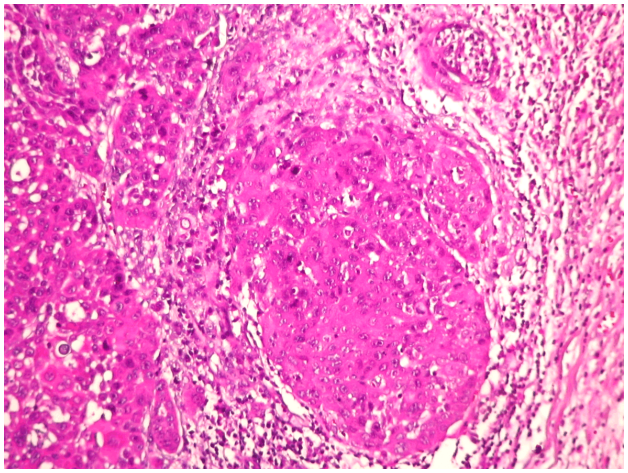

Figure 19 – *Lymph node metastasis in moderately differentiated squamous cell carcinoma. HE staining, ×200.*

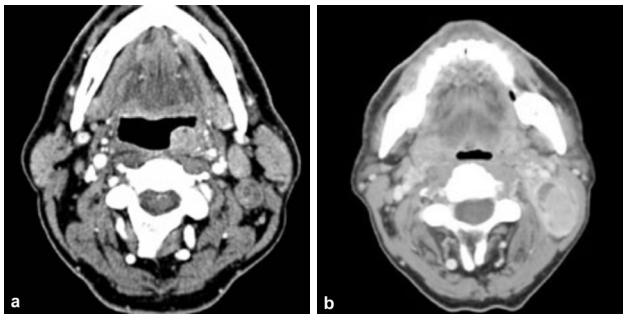

Figure 20 – *(a and b) Cervical computer tomography with contrast media – lymph node metastases with necrosis in poorly differentiated pharyngeal squamous cell carcinoma.*

Discussion

The purpose of this paper is not to contest the supremacy of morphopathology and particularly histopathology in assessing the actual characteristics of a malignant tumor.

It is found that most cases of moderately differentiated SCC predominantly affects oropharynx, 40.9% of these cases, or hypopharynx, respectively 54.55%, while the poorly differentiated, when detection is extended to both regions. The results are similar to those reported by Thompson [12] and Ala Eddine *et al.* [7] said that more than 70% of SCC are moderately or poorly differentiated.

In this regard were used the dimensional criterion, that of locoregional tumor invasion and lymphatic metastasis. The imaging evaluation of a tumor requires measuring it, so the consideration of a dimensional criterion. In our study, we chose splitting the dimensional criterion in three levels, from type T stadialization of oropharyngeal squamous cell carcinoma.

The assessment of the dimensional criteria is not included in the criteria for T stadialization of nasopharyngeal squamous cell carcinoma, nor in those of hypopharyngeal squamous cell carcinoma. At the same time, T stadialization of hypopharyngeal squamous cell carcinoma sets the tumor extension at stage T1 as a tumor restricted to one of the three sectors of the hypopharynx [10, 15–17]. Considering the anatomical dimensional criteria of the hypopharynx, a stage T1 tumor may be limited dimensionally both to subdivision "<2 cm" and the subdivision "2–4 cm".

Regarding the nasopharyngeal squamous cell carcinoma, a tumor in stage T1, based on the anatomic dimensional criteria, cannot be larger than 2 cm.

In our study, 77.3% of squamous cell carcinomas were moderately differentiated diagnosis between 2 and 4 cm. Ala Eddine *et al.* [7] and Dubrulle *et al.* [9] report a rate of 80–90% of squamous cell carcinoma moderate differentiated with size between 2–4 cm.

Regarding the extension of the tumor, computed tomography exam results are comparable to those of a morphopathological examination, but cannot be compared with those of a histopathological examination. Preoperative imaging detects muscle, bone or vascular invasion, but the gold standard belongs to pathology. Computed tomography can help the surgeon in determining the operator strategy and the pathological examination confirms the suppositions of the imagist and the surgeon.

In our study degree of tumor extension, evaluated imaging corresponds to 81.5%, compared with morphopatological analysis.

Thompson [12] and Chong [15] evaluate tumor volumetric percentages greater than 80% compared with pathological results. However, the histopathological examination establishes with certainty the type of squamous cell carcinoma and makes its correct stadialization.

The assessment of the structural criterion computed tomography detectable can guide the surgeon, and eventually may guide the anatomopathologist in the histopathological staging.

The assessment of the contrast medium enhancement administered during computed tomography examination is useful only to the imagist in assessing the malignancy characteristics of the tumor. The dimensional criterion of adenopathies is, imagistically, only an indicative criterion in assessing the TNM stadialization of a malignant tumor.

Highlighting on the computed tomography scan of any cervical lymph node, at the same time with squamous cell carcinoma, is a warning and a certainty of tumor malignancy.

Thus, 95.45% of all moderately differentiated squamous cell carcinoma showed to computed tomography examination lymph nodes with malignant characters, and if poorly differentiated squamous cell carcinoma adenopathies were found in 100% of cases.

A meta-analysis by Dünne *et al.* [18] and Zhong *et al.* [19] showed a 5-year survival rate between 17% and 55.8% for SCC with cervical node metastases and 44.6–76% for SCC patients without cervical node metastases [20].

The occurrence of necrosis in lymph node metastases is directly related to their production mechanism [21, 22]. At the same time is observed the importance of the dimensional criterion and of the degree of differentiation of the type of squamous cell carcinoma [23]. From the paper, it results that in the case of squamous cell carcinoma, regardless of localization, lymph nodes under 3 cm usually do not necrosis. It is also worth noting that the occurrence of necrosis in case of poorly differentiated squamous cell carcinoma is an essential objective in imaging analysis, considering the almost entirely occurrence of this kind of change in relation to the other two types of squamous cell carcinoma [24, 25].

Conclusions

A computed tomography examination correctly and completely performed can appreciate the volume of the tumor and may guide on the degree of its extension. Computed tomography may be similar with morphopathology, but cannot compete with histopathology. Computed tomography detects the presence of adenopathies and can make assessments on the degree of benignity or malignancy of the tumor. Dimensional analysis criteria of lymph nodes are very important for diagnosis. Structural analysis of lymph nodes is only indicative in relation to histopathology. TNM stadialization performed because of computed tomography examination can guide the surgeon on the surgical technique strategy and potentially provide global information on the tumor to the anatomopathologist. The existence of any kind of radioimaging exploration cannot replace the anatomopathological examination. The histopathological and immunohistochemical examinations bring exquisite data for establishing the positive and differential diagnosis, the prognosis and the accurate treatment plan.

Conflict of interests

The authors declare that they have no conflict of interests.

Author contribution

All authors contributed equally to the manuscript.

References

[1] Upile T, Fisher C, Jerjes W, El Maaytah M, Singh S, Sudhoff H, Searle A, Archer D, Michaels L, Hopper C, Rhys-Evans P, Howard D, Wright A. Recent technological developments: *in situ* histopathological interrogation of surgical tissues and resection margins. Head Face Med, 2007, 3:13.

[2] Genden EM, Ferlito A, Silver CE, Takes RP, Suárez C, Owen RP, Haigentz M Jr, Stoeckli SJ, Shaha AR, Rapidis AD, Rodrigo JP, Rinaldo A. Contemporary management of cancer of the oral cavity. Eur Arch Otorhinolaryngol, 2010, 267(7): 1001–1017.

[3] Tshering Vogel DW, Zbaeren P, Thoeny HC. Cancer of the oral cavity and oropharynx. Cancer Imaging, 2010, 10:62–72.

[4] Brockenbrough JM, Petruzzelli GJ, Lomasney L. DentaScan as an accurate method of predicting mandibular invasion in patients with squamous cell carcinoma of the oral cavity. Arch Otolaryngol Head Neck Surg, 2003, 129(1):113–117.

[5] Rajesh A, Khan A, Kendall C, Hayter J, Cherryman G. Can magnetic resonance imaging replace single photon computed tomography and computed tomography in detecting bony invasion in patients with oral squamous cell carcinoma? Br J Oral Maxillofac Surg, 2008, 46(1):11–14.

[6] Park JO, Jung SL, Joo YH, Jung CK, Cho KJ, Kim MS. Diagnostic accuracy of magnetic resonance imaging (MRI) in the assessment of tumor invasion depth in oral/oropharyngeal cancer. Oral Oncol, 2011, 47(5):381–386.

[7] Ala Eddine C, Piekarski JD, Benamor M. Tumors of the oropharynx and oral cavity: MR, CT, PET-CT imaging. J Radiol, 2008, 89(7–8 Pt 2):968–983.

[8] Hermans R, Van den Bogaert W, De Vuysere S, Baert AL, Marchal G. Computed tomography of laryngeal carcinoma: technique, imaging findings and implications for radiation therapy. J Belge Radiol, 1998, 81(4):190–198.

[9] Dubrulle F, Martin-Duverneuil N, Moulin G. Imagerie en ORL. Elsevier–Masson, 2010, 115–165, 181–201.

[10] Chong VFH, Zhou JY, Khoo JBK, Huang J, Lim TK. Nasopharyngeal carcinoma tumor volume measurement. Radiology, 2004, 231(3):914–921.

[11] Barnes L, Eveson JW, Reichart P, Sidransky D (eds). Pathology and genetics head and neck tumours. World Health Organization Classification of Tumours, IARC Press, Lyon, 2005, 83–118.

[12] Thompson LDR. Squamous cell carcinoma variants of the head and neck. Curr Diagn Pathol, 2003, 9(6):384–396.

[13] Popescu B, Popescu CR, Grigore R, Mogoantă CA, Ioniţă E, Moculescu C, Berteşteanu ŞV. Morphology and morphopathology of hypopharyngo-esophageal cancer. Rom J Morphol Embryol, 2012, 53(2):243–248.

[14] Suzuki H, Saito Y, Ikehara H, Oda I. Evaluation of visualization of squamous cell carcinoma of esophagus and pharynx using an autofluorescence imaging videoendoscope system. J Gastroenterol Hepatol, 2009, 24(12):1834–1839.

[15] Chong VFH. Neoplasms of the nasopharynx. In: Hermans R (ed). Head and neck cancer imaging. Medical Radiology – Diagnostic Imaging Series, Springer, Berlin–Heidelberg, 2006, 143–162.

[16] Fleming ID, Cooper JS, Henson DE, Hutter RVP, Kennedy BJ, Murphy GP, O'Sullivan B, Sobin LH, Yarbro JW (eds). AJCC manual for staging of cancer. 5th edition, J.B. Lippincott–Raven Publishers, Philadelphia–New York, 1997, 21–23.

[17] Som PM, Curtin HD, Mancuso AA. Imaging-based nodal classification for evaluation of neck metastatic adenopathy. AJR Am J Roentgenol, 2000, 174(3):837–844.

[18] Dünne AA, Müller HH, Eisele DW, Kessel K, Moll R, Werner JA. Meta-analysis of the prognostic significance of perinodal spread in head and neck squamous cell carcinomas (HNSCC) patients. Eur J Cancer, 2006, 42(12):1863–1868.

[19] Zhong J, Lu Z, Xu L, Dong L, Qiao H, Hua R, Gong Y, Liu Z, Hao C, Liu X, Zong C, He L, Liu J. The diagnostic value of cervical lymph node metastasis in head and neck squamous carcinoma by using diffusion-weighted magnetic resonance imaging and computed tomography perfusion. BioMed Res Int, 2014, 2014:260859.

[20] Uribe S, Rojas LA, Rosas CF. Accuracy of imaging methods for detection of bone tissue invasion in patients with oral squamous cell carcinoma. Dentomaxillofac Radiol, 2013, 42(6):20120346.

[21] Buckley JG, MacLennan K. Cervical node metastases in laryngeal and hypopharyngeal cancer: a prospective analysis of prevalence and distribution. Head Neck, 2000, 22(4):380–385.

[22] Gross ND, Ellingson TW, Wax MK, Cohen JI, Andersen PE. Impact of retropharyngeal lymph node metastasis in head and neck squamous cell carcinoma. Arch Otolaryngol Head Neck Surg, 2004, 130(2):169–173.

[23] Adelstein DJ, Ridge JA, Gillison ML, Chaturvedi AK, D'Souza G, Gravitt PE, Westra W, Psyrri A, Kast WM, Koutsky LA, Giuliano A, Krosnick S, Trotti A, Schuller DE, Forastiere A, Ullmann CD. Head and neck squamous cell cancer and the human papillomavirus: summary of a National Cancer Institute State of the Science Meeting, November 9–10, 2008, Washington, D.C. Head Neck, 2009, 31(11):1393–1422.

[24] Lee WC, Walsh RM, Tse A. Squamous cell carcinoma of the pharynx and larynx presenting as a neck abscess or cellulitis. J Laryngol Otol, 1996, 110(9):893–895.

[25] Kato H, Kanematsu M, Watanabe H, Mizuta K, Aoki M. Metastatic retropharyngeal lymph nodes: comparison of CT and MR imaging for diagnostic accuracy. Eur J Radiol, 2014, 83(7):1157–1162.

Corresponding author
Ana Magdalena Bratu, MD, PhD, Department of Radiology and Medical Imaging, Colţea Clinical Hospital, 1 Ion C. Brătianu Avenue, 30174 Bucharest, Romania; Phone +40723–279 039, e-mail: anaconst@clicknet.ro

Received: October 3, 2014

Accepted: March 21, 2015