ORIGINAL PAPER

RJME
Romanian Journal of Morphology & Embryology
http://www.rjme.ro/

Considerations on morphological abnormalities of permanent teeth in children with cleft lip and palate

ANCA MARIA RĂDUCANU[1)], ANDREEA CRISTIANA DIDILESCU[2)], ION-VICTOR FERARU[1)], MIHAELA ADINA DUMITRACHE[3)], TUDOR ALEXANDRU HĂNŢOIU[4)], ECATERINA IONESCU[5)]

[1)] *Department of Pedodontics, Faculty of Dental Medicine, "Carol Davila" University of Medicine and Pharmacy, Bucharest, Romania*

[2)] *Department of Embryology, Faculty of Dental Medicine, "Carol Davila" University of Medicine and Pharmacy, Bucharest, Romania*

[3)] *Department of Oral Health, Faculty of Dental Medicine, "Carol Davila" University of Medicine and Pharmacy, Bucharest, Romania*

[4)] *Department of Odontology and Periodontology, Faculty of Dental Medicine, University of Medicine and Pharmacy of Tirgu Mures, Romania*

[5)] *Department of Orthodontics and Dento-Facial Orthopedics, Faculty of Dental Medicine, "Carol Davila" University of Medicine and Pharmacy, Bucharest, Romania*

Abstract

Oral clefts are commonly associated with dental anomalies of number, size, shape, structure, position and eruption affecting both dentitions. Dental malformations may affect the development, growth and functions of the dento-maxillary apparatus (chewing, aesthetics, speech). The purpose of this paper was to assess the dental morphological variations in a group of patients with cleft lip and/or palate (CLP), as compared with a group of healthy subjects. The study sample included 48 patients with various types of CLP (15 girls and 33 boys) aged between 12.6 years and 17.3 years. The control group (without CLP) consisted of 1447 patients (545 girls and 903 boys). The proportion of patients with dental shape anomalies in the control group was 8.6%, while the proportion of patients with dental shape anomalies in the CLP group was 56.3% ($p<0.01$). With this regards, the frontal area was more affected in CLP group than controls. The most common morphological abnormality in the control group was supplementary cusp, while in the CLP sample it was dilaceration. Teeth from the dental hemiarch affected by CLP were most affected in their morphology.

Keywords: cleft lip and palate, dental shape anomalies, dilacerations.

Introduction

Clefts lip and palate (CLP) are the most common facial birth defects with a prevalence varying from one in 500 to one in 2500 live births, depending on the geographic origin and ethnic background [1, 2]. CLP are fusion disorders that manifest as partial or complete dehiscence that divide abnormally facial structures [1] and which appear between the 4th and 12th weeks of intrauterine life, period during which the embryonic development of the face and palate are taking place [3].

Oral clefts are commonly associated with dental anomalies of number, size, shape, structure, position and eruption affecting both dentitions [1, 2, 4, 5].

Dental abnormalities result as an embryologic disorder in the anatomical development of the lip, palate, tooth buds and from the surgical procedures for lip and palate repair [6].

Most malformed teeth occur by disrupting mainly the morphodifferentiation stage of tooth development and are manifested as alterations in crown and root form [7, 8].

The aim of this study was to assess the dental morphology anomalies in a group of patients with CLP, as compared with a group of healthy subjects.

Materials and Methods

This retrospective study was conducted on clinical records of patients examined and treated over a period of 10 years (2004–2014) in the Department of Pediatric Dentistry, "Carol Davila" University of Medicine and Pharmacy, Bucharest, Romania. The study was conducted on two affected by CLP study samples (patients and teeth) and two control groups (patients and teeth).

Subjects

The patients study sample included 48 subjects with various types of CLP (15 girls and 33 boys) aged between 12 years six months and 17 years three months (mean age 15.05±0.23 years). The study sample was selected from an initial sample of patients of 1495 subjects with/without CLP (559 girls and 936 boys), aged between 11 years and six months and 17 years and eight months (mean age 14.24±0.09 years).

The patients control group included 1447 subjects (545 girls and 903 boys).

The patients' inclusion criteria for this study were: patients with complete clinical records and good quality of radiographs and dental casts, healthy patients for the control group, patients with CLP for the study group

without associated syndromes or relevant medical diseases and patients with permanent dentition only.

Teeth

The teeth samples (303 teeth) consisted of 51 permanent teeth with shape anomalies in CLP patients and 252 teeth with shape anomalies in the control group.

The research was based on the analysis of the following data obtained from the clinical observation charts:

▪ personal data: gender, date of birth;

▪ clinical data: teeth with morphological anomalies, type of the shape anomaly;

▪ type of cleft – the CLP were classified in: complete unilateral clefts (CUC), complete bilateral clefts (CBC), complete anterior unilateral clefts (CAUC), complete posterior clefts (CPC), partial posterior cleft (PPC).

The evaluation of the teeth with shape anomalies was based on the analysis of the patients' records, radiographs and study models. Third molars were excluded from the study. The FDI (*Fédération Dentaire Internationale*) index of tooth notation was used to identify teeth. Clinical and radiological investigations were used to diagnose dental shape anomalies in the permanent dentition.

The following dental anomalies were evaluated: supernumerary cusps, peg shaped incisors, chisel shaped incisors, enamel hypoplasia, dilacerations, double teeth, dens invaginatus.

The statistical analysis of the recorded data was performed using Stata IC11 software version 2009 (Stata Corp LP, Texas, USA). In order to test the differences between variables, Pearson's *chi*-square test was used, for a statistical confidence level of 95%.

Results

The different types of CLP were recorded as follows: 23 (47.9%) complete unilateral clefts, 15 (31.3%) complete bilateral clefts, five (10.4%) complete anterior unilateral clefts, four (8.3%) complete posterior clefts, one (2.1%) partial posterior cleft. The frequency of CLP was higher on the left side (39.6%) than on the right side (18.8%). Patients with CLP presented an average of 1.06% shape teeth anomalies while patients in the control group presented an average of 0.17% malformed teeth.

Dental shape anomalies were detected in 27 (nine girls and 18 boys) of the patients in the CLP sample (56.3%) and in 124 (49 girls and 75 boys) of the patients in the control group (8.6%). The malformed teeth were 51 in patients with clefts and 252 in patients in the control group.

The tooth shape anomalies recorded in both patients with CLP (by type of cleft) and non-CLP patients are presented in Table 1.

Table 1 – ***Distribution of shape anomalies in patients in the CLP sample (by type of cleft) and control group***

Type of shape anomaly	CLP sample					Control group
	CAUC	*CPC*	*CUC*	*CBC*	*Total*	
Supplementary cusp	0	2 (100%)	12 (40%)	4 (23.5%)	18 (35.3%)	206 (81.7%)
Enamel hypoplasia	0	0	1 (3.3%)	1 (5.9%)	2 (3.9%)	17 (6.7%)
Double tooth	0	0	0	0	0	13 (5.2%)
Peg shaped tooth	1 (50%)	0	2 (6.7%)	5 (29.4%)	8 (15.7%)	10 (4%)
Dilaceration	1 (50%)	0	15 (50%)	7 (41.2%)	23 (45.1%)	3 (1.2%)
Chisel shape tooth	0	0	0	0	0	2 (0.8%)
Dens invaginatus	0	0	0	0	0	1 (0.4)

CLP: Cleft lip and palate; CAUC: Complete anterior unilateral cleft; CPC: Complete posterior cleft; CUC: Complete unilateral cleft; CBC: Complete bilateral cleft.

Supplementary cusps, which represent extra or additional cusps, were found in 224 teeth in both samples of patients. We found four types of additional cusps: Carabelli trait (an extra cusp situated on the mesio-palatal line angle of maxillary first molars), the paramolar Bolk's cusp (situated on the buccal surface of the second permanent molar) (Figure 1), talon cusp (situated on the palatal surface of the permanent incisors particularly in the upper jaw) (Figure 2), dens evaginatus (situated in the middle of the occlusal surface of the lateral teeth, especially in premolars) (Figure 3) [9–11].

Dilaceration (Figures 4 and 5), a morphological anomaly consisting in an angulation, or a sharp bend or curve, in the root or crown of a formed tooth, was found in 26 (8.6%) teeth. Peg morphology (Figure 6), affecting usually the upper lateral incisor, was found in 18 (5.9%) teeth.

The double teeth were represented by both fused and geminated teeth. Dental fusion is the union of two normally separated tooth germs and geminated teeth is the division of a tooth germ. The number of double teeth was 13 (4.3%).

Chisel shaped tooth represents a tooth whose mesial and distal surfaces are more convergent than normally towards the incisal edge. Two teeth were chisel shaped in the control group (0.7%).

Enamel hypoplasia, defined as an enamel defect in which a tooth has less enamel than usual, was found in 19 (6.3%) teeth.

Dens invaginatus, also known as dens in dente, is a shape abnormality showing a large spectrum of crown morphological variations. The affected teeth radiographically present an infolding of enamel and dentine which may extend more deeply into the pulp cavity and into the root. In our study, one tooth (0.3%) presented dens invaginatus.

The teeth with shape anomalies were analyzed according with their position on the dental arch (frontal and lateral areas) of both patients with clefts and patients in the control group. In the frontal area, there were 32 teeth in patients with CLP and 36 in patients in the control group (representing 62.7% and 14.3% respectively of the total number of malformed teeth in each of the two samples). The difference registered between the frequency

of malformed teeth in the frontal area in CLP and non-CLP patients was statistically significant ($p<0.01$), while in the lateral area the prevalence of malformed teeth did not register statistically significant differences.

A significant association was found between the cleft side (left/right) and number of teeth with morphological abnormalities on the affected side ($p=0.002$).

The distribution of the teeth with shape anomalies according to the type of CLP is presented in Table 2.

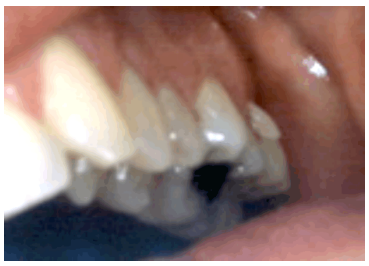

Figure 1 – ***Bolk cusp on 2.7.***

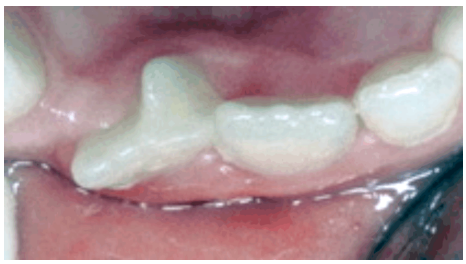

Figure 2 – ***Talon cusp on 4.1.***

Figure 3 – ***Dens evaginatus on 1.6.***

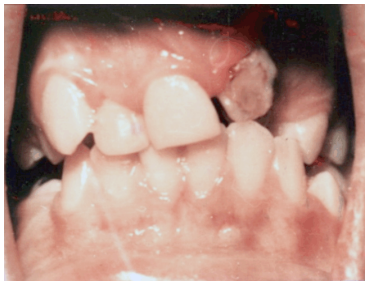

Figure 4 – ***Crown-root dilaceration and enamel hypoplasia in 2.1 in a patient with CUC.***

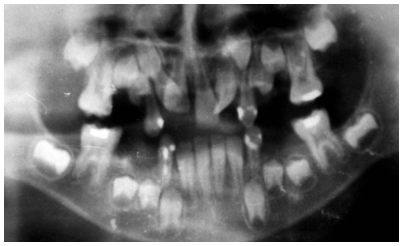

Figure 5 – ***Panoramic radiograph of patient with CBC with dilaceration in 2.2.***

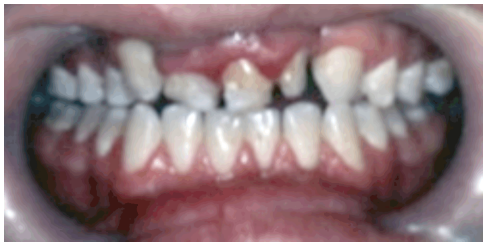

Figure 6 – ***Peg shaped 2.2 in a patient with CBC.***

Table 2 – ***Type of tooth with shape anomaly according to the type of CLP***

Type of tooth	CAUC (2)		CPC (2)		CUC (30)		CBC (17)		Total (51)	
	n	*%*	*n*	*%*	*n*	*%*	*n*	*%*	*n*	*%*
11	0	0	0	0	4	13.3	1	5.9	5	9.8
12	0	0	0	0	3	10	3	17.6	6	11.8
15	0	0	0	0	1	3.3	1	5.9	2	3.9
16	0	0	1	50	5	16.7	1	5.9	7	13.7
21	1	50	0	0	7	23.3	5	29.4	13	25.5
22	1	50	0	0	3	10	4	23.5	8	15.7
25	0	0	0	0	1	3.3	1	5.9	2	3.9
26	0	0	1	50	5	16.7	1	5.9	7	13.7
41	0	0	0	0	1	3.3	0	0	1	2

CLP: Cleft lip and palate; CAUC: Complete anterior unilateral cleft; CPC: Complete posterior cleft; CUC: Complete unilateral cleft; CBC: Complete bilateral cleft.

Taking into account the data in the literature indicating that maxillary incisors are the most frequently affected teeth in patients with CLP, the distribution of shape anomalies of central and lateral incisors in CLP and non-CLP patients was analyzed. Thus, 18 (78.3%) of the central upper incisors were recorded in CLP patients and five (21.7%) in non-CLP patients, while 14 (40%) of the lateral upper incisors were recorded in CLP patients and 21 (60%) in non-CLP patients. Differences recorded between the frequencies of malformed incisors in the two samples of patients were statistically significant ($p=0.004$).

Dilaceration was the most frequent type of shape anomaly in the CLP patients (23 cases). In the control group, dilaceration was found in only three cases. The difference between the two samples was statistically significant ($p<0.001$). The same situation was recorded for peg shaped teeth (CLP sample: 15.7%; control group: 4%) ($p=0.001$).

Discussion

Dental malformations may affect the development, growth and functions of the dento-maxillary apparatus (chewing, aesthetics, speech) [3, 12], thus making the treatment more difficult and reducing the later treatment options, especially prosthetic and orthodontic. Children with cleft lip and/or palate commonly require multi-disciplinary treatments [13].

Our study indicated that the prevalence of CLP was 3.2%. This percent is higher compared to data in the literature, which indicates a prevalence of 0.9–2.21 CLP per 1000 live births. This situation is explained by the fact that a large number of patients who received surgical treatment in the "Prof. Dr. Dan Theodorescu" Oral and Maxillofacial Surgery Hospital, Bucharest were directed to our clinic for post-operative treatment [14, 15].

Previous studies suggested that CLP occurs more frequently in boys, issue confirmed by the present study [11, 14–17]. Many other studies indicate that these

congenital malformations are accompanied by a considerable number of anomalies in the shape of permanent teeth [1, 4, 11, 18].

Regarding morphological abnormalities, they appear by impairment of organogenesis of the midfacial skeleton under the influence of varied etiological factors (genetic, inherited, unknown, environmental factors). They may occur independently (non-syndromic) or within complex syndromes associated with multiple congenital malformations [3, 6, 19]. The CLP patients in our study sample did not present associated syndromes or relevant general diseases.

Dental anomalies are more prevalent in CLP patients around the cleft and occur in patients with oral clefts with a higher frequency than in the general population [6, 11, 20, 21]. Our study showed that the proportion of patients with shape anomalies in the CLP sample was significantly higher than in the control group. Although the reported proportions differ, the results are in agreement with other literature studies [1, 17, 18], being close to data reported by Boehn and Helquist *et al.* (cited by Wong *et al.*, 2012) [11].

Previous studies showed that in CLP patients, the maxillary lateral incisor was the tooth most frequently affected by dental anomalies, including abnormalities of number and size [2, 4, 16, 22, 23]. The results of our study indicate that in the frontal area the central upper incisor was more frequently affected by shape anomalies than the upper lateral incisor.

The number of tooth anomalies is positively associated with the severity of the cleft [1, 16]. However, dental abnormalities can be present outside the cleft area [1, 11]. The results of the present study indicate that the frequency of teeth with shape anomalies in patients with CLP was higher in the frontal area than in the control group. The frequency of teeth with shape anomalies was greater on the affected side. Also, the recorded number of malformed teeth in the mandibular arch was much lower than in the maxillary arch. These results suggest that dental morphology anomalies appear particularly in areas affected by CLP, as also previously shown by Lourenço Ribeiro *et al.* (2003) and Akcam *et al.* (2010) [16, 17, 24].

The literature indicates that the most common dental shape abnormalities are peg-shaped incisors, supernumerary or exaggerated tubercles, enamel hypoplasia, dilacerations, double teeth, screwdriver-shaped incisors [13], dens evaginatus or talon cusp, taurodontism [17]. With this regard, the most common variance pattern in the control group was supplementary cusps, while in the CLP sample it was dilaceration, which is in disagreement with Lourenço Ribeiro *et al.* (2003) [16] who reported a higher prevalence of conical teeth (situated on the third position in our study). However, the high number of supplementary cusps recorded in our study may be explained by the inclusion of Carabelli traits.

Clefts, as well as malformed teeth, were more prevalent on the left side. This result was previously confirmed by other studies [1, 2, 17, 25].

The pediatric dentist should inform the patient and his parents about dental shape anomalies as part of the traditional problems associated with clefting. The patient and the parents must know that various anomalies of tooth morphology, affecting most often the upper incisors, are frequently seen in association with complete unilateral and bilateral clefts of the palate [26]. Dental shape abnormalities may affect oral functions and require a complex, multidisciplinary rehabilitation treatment [13, 26].

Conclusions

Perturbations of upper lip and palate development conducted to increase of dental morphology anomalies. The teeth from the dental hemiarch affected by CLP were most affected in their morphology. Dilaceration and peg shaped tooth were the most common tooth shape anomalies in the CLP affected areas, while supplementary cusp was the most frequently morphological abnormality encountered in the control group.

Conflict of interests

The authors declare that they have no conflict of interests.

Author contribution

All authors contributed equally in the elaboration of the study.

References

[1] Qureshi WA, Beiraghi S, Leon-Salazar V. Dental anomalies associated with unilateral and bilateral cleft lip and palate. J Dent Child (Chic), 2012, 79(2):69–73.

[2] de Menezes LM, Rizzatto SMD, Azeredo F, Vargas DA. Characteristics and distribution of dental anomalies in a Brazilian cleft population. Rev Odonto Ciênc, 2010, 25(2): 137–141.

[3] Freitas JAS, das Neves LT, de Almeida ALPF, Garib DG, Trindade-Suedam IK, Yaedú RYF, Lauris RCMC, Soares S, Oliveira TM, Pinto JHN. Rehabilitative treatment of cleft lip and palate: experience of the Hospital for Rehabilitation of Craniofacial Anomalies/USP (HRAC/USP) – Part 1: overall aspects. J Appl Oral Sci, 2012, 20(1):9–15.

[4] Wu TT, Chen PKT, Lo LJ, Cheng MC, Ko EWC. The characteristics and distribution of dental anomalies in patients with cleft. Chang Gung Med J, 2011, 34(3):306–314.

[5] Ranta R. A review of tooth formation in children with cleft lip/ palate. Am J Orthod Dentofacial Orthop, 1986, 90(1):11–18.

[6] Kaleem OM, Bashir U. Frequency of cleft lip and palate and associated dental anomalies at Islamic International Dental Hospital, Islamabad. Pak Oral Dental J, 2011, 31(2):352–356.

[7] Slayton RL, Congenital genetic disorders and syndromes. In: Pinkham JR, Casamassimo PS, Fields HW Jr, McTigue DJ, Nowak AJ. Pediatric dentistry: infancy through adolescence. 4th edition, Elsevier–Saunders, Philadelphia–London, 2005, 257–274.

[8] Dummett CO Jr. Anomalies of the developing dentition. In: Pinkham JR, Casamassimo PS, Fields HW Jr, McTigue DJ, Nowak AJ. Pediatric dentistry: infancy through adolescence. 4th edition, Elsevier–Saunders, Philadelphia–London, 2005, 61–72.

[9] Brand RW, Isselhard DE. Anatomy of orofacial structures – a comprehensive approach. Enhanced 7th edition, Elsevier–Mosby, 2014, 167.

[10] Kustaloglu OA. Paramolar structures of the upper dentition. J Dent Res, 1962, 41(1):75–83.

[11] Wong HM, Lai MC, King NM. Dental anomalies in Chinese children with cleft lip and palate. Dentistry, 2012, 2(3):127.

[12] Millett D, Welbury R. Orthodontics and paediatric dentistry. Churchill Livingstone, 2000, 79.

[13] Hodgkinson PD, Brown S, Duncan D, Grant C, McNaughton A, Thomas P, Mattick CR. Management of children with cleft lip and palate: a review describing the application of multi-

disciplinary team working in this condition based upon the experiences of a regional cleft lip and palate centre in the United Kingdom. Fetal Maternal Med Rev, 2005, 16(1):1–27.
[14] Martelli-Junior H, Porto LV, Martelli DR, Bonan PR, Freitas AB, Della Coletta R. Prevalence of nonsyndromic oral clefts in a reference hospital in the State of Minas Gerais, Brazil, between 2000–2005. Braz Oral Res, 2007, 21(4):314–317.
[15] Mossey PA, Modell B. Epidemiology of oral clefts 2012: an international perspective. In: Cobourne MT (ed). Cleft lip and palate: epidemiology, aetiology and treatment. Book Series: Vol. 16 – "Frontiers of Oral Biology", S. Karger AG, Basel, 2012, 3–5.
[16] Lourenço Ribeiro L, Teixeira Das Neves L, Costa B, Ribeiro Gomide M. Dental anomalies of the permanent lateral incisors and prevalence of hypodontia outside the cleft area in complete unilateral cleft lip and palate. Cleft Palate Craniofac J, 2003, 40(2):172–175.
[17] Akcam MO, Evirgen S, Uslu O, Memikoğlu UT. Dental anomalies in individuals with cleft lip and/or palate. Eur J Orthod, 2010, 32(2):207–213.
[18] Abd Rahman N, Abdullah N, Samsudin AR, Naing Mohd Ayub Sadiq L. Dental anomalies and facial profile abnormality of the non-syndromic cleft lip and palate children in Kelantan. Malays J Med Sci, 2004, 11(2):41–51.
[19] King N, Reid J, Jayuasekera T, Hall R, Lopacki S. Management of cleft lip and palate. In: Cameron AC, Widmer RP (eds). Handbook of pediatric dentistry. 2nd edition, Mosby, 2003, 322–341.
[20] Meadors LW, Jones HL. Fused primary incisors with succedaneous supernumerary in the area of a cleft lip: case report. Pediatr Dent, 1992, 14(6):397–399.
[21] de Lima Pedro R, Faria MDB, de Castro Costa M, Vieira AR. Dental anomalies in children born with clefts: a case-control study. Cleft Palate Craniofac J, 2012, 49(6):e64–e68.
[22] Vichi M, Franchi L. Abnormalities of the maxillary incisors in children with cleft lip and palate. ASDC J Dent Child, 1995, 62(6):412–417.
[23] Galie N, Enache M, Podoleanu L, David D, Podoleanu E, Spînu T, Olteanu M. Evaluation of dental and maxillary development in patients with cleft lip alveolus. Rom J Morphol Embryol, 2009, 50(1):91–95.
[24] Camporesi M, Baccetti T, Marinelli A, Defraia E, Franchi L. Maxillary dental anomalies in children with cleft lip and palate: a controlled study. Int J Paediatr Dent, 2010, 20(6):442–450.
[25] Scully C, Welbury R. Color atlas of oral diseases in children and adolescents. Wolfe Publishing, 1994.
[26] Jones JE, Sadove AM, Dean JA, Huebener DV. Chapter 28: Multidisciplinary team approach to cleft lip and palate management. In: McDonald RE, Avery DR, Dean JA (eds). Dentistry for the child and adolescent. 8th edition, Mosby–Elsevier, 2004, 688–689.

Corresponding author
Ion-Victor Feraru, Assistant Professor, DMD, Department of Pedodontics, Faculty of Dental Medicine, "Carol Davila" University of Medicine and Pharmacy, 12 Ionel Perlea Street, 010209 Bucharest, Romania; Phone +40745–064 014, e-mail: victor.feraru@gmail.com

Received: December 10, 2014

Accepted: May 27, 2015