ORIGINAL PAPER

RJME
Romanian Journal of Morphology & Embryology
http://www.rjme.ro/

Age and individual anatomical variability of intercostal nerves in human fetuses

TATYANA VLADIMIROVNA KHMARA[1)], ILYA ILYICH OKRYM[2)], IGOR IVANOVICH ZAMORSKII[3)], SVITLANA DMYTRIVNA NOVYCHENKO[3)], OLENA YURIVNA HAHEN[4)], IVAN IVANOVICH DRONYK[4)]

[1)]*Department of Human Anatomy named after M. H. Turkevych, Bukovinian State Medical University, Chernivtsi, Ukraine*
[2)]*Department of Histology, Cytology, and Embryology, Bukovinian State Medical University, Chernivtsi, Ukraine*
[3)]*Department of Pharmacology, Bukovinian State Medical University, Chernivtsi, Ukraine*
[4)]*Department of Surgical Stomatology and Maxillofacial Surgery, Bukovinian State Medical University, Chernivtsi, Ukraine*

Abstract

Performing fetal operations on the walls of the thorax and abdomen requires detailed information dealing with the anatomical variability of the intercostal nerves (IN) in human fetuses. Therefore, our study aimed at determining the topographic and anatomical characteristics of the I–XII IN during the period of human ontogenesis. The study involved 70 specimens of fetuses aged 4–10 months, by means of macromicroscopic preparation, superficial staining of dissected vessels and nerves and morphometry. The variability of the topography and asymmetry of the trunks of IN and their branches were revealed. The direction of the lateral musculocutaneous branches of the inferior IN does not coincide with the direction of the muscle bundles of the external abdominal oblique muscle. The branches of the I IN are functionally different, since the superior branch branches out in the skin and vessels, and the inferior one – in the stratum of the internal intercostal muscle. The anterior musculocutaneous branches of the II–VII IN occur in the front of the parasternal neurovascular bundle and are related with each other, with parasternal nerve or with the nerve plexus of the internal thoracic artery. The trunks of adjacent IN relate to one another by means of rare connecting branches, numerous and diverse in shape links are observed between the anterior and lateral musculocutaneous branches of the VIII–XII IN in the area of the anterior-lateral regions of the abdominal wall. The connecting branches descend from the nodes of the thoracic section of the sympathetic trunk to the IN.

Keywords: intercostal nerves, anatomical variability, fetus, man.

Introduction

Nowadays, the frequency of chest traumas due to different situations – military actions, road, domestic, professional and sport accidents – is extremely high. Fracture of the ribs is the most frequent injury in the case of chest trauma. Intercostal nerves (IN), as a rule, pass below the intercostal artery and usually beyond the limits of the costal sulcus, in the result of which they are more often traumatically damaged than the intercostal vessels.

IN and their branches involved in innervations of the muscles and skin of the anterior-lateral abdominal walls are often damaged during laparotomy and lumbotomy, which is one of the causes of atrophy of the muscles, the formation of postoperative hernia, trophic ulcers, pain syndromes, and other complications [1, 2].

In the region of the anterior abdominal wall, the number of IN varies from one to four pairs, but most often there are two pairs of IN (60% of observations) observed [3]. IN penetrate *rectus abdominis* muscles, as a rule, through their external edges (52%), or from their posterior surface (39%). In persons with a posterior variant of IN penetration into the *rectus abdominis* muscles, the posterior separation hernioplasty will be accompanied by a maximum risk of damage to the nerve trunks and, consequently, the emergence of chronic pain syndrome during the post-operative period [4].

Performing surgical interventions on the walls of the thorax and abdomen (IN blockade, thoracotomy, thoracoplasty, puncture of the pleural cavity, ligation of internal thoracic arteries in case of angina, dissecting abdominal wall, myoplasty, neurectomy, etc.) requires detailed knowledge of the structure and topography of the anterior and lateral thoracic and abdominal cutaneous branches of IN. The information about the links between the IN with each other and with the nerves that accompany the internal thoracic and inferior epigastric arteries, the anterior and lateral musculocutaneous branches of the IN is of certain interest for morphologists and clinicians [5–9].

The development and application of methods of surgical interventions on the structures of the brachial plexus requires careful study of the topographic and anatomical peculiarities of the anterior branches of the cervical C5, C6, C7, C8 and thoracic Th1 spinal nerves [10].

Active development of fetal surgery in recent years [11–16] puts before researchers a whole range of questions about the anatomical variability of organs and structures in the human fetuses of different ages. Fetal operations, like no other interventions, require detailed topographical-anatomical justification and detailed information on the fetal topography of organs and structures [17], including those related to IN during the fetal period of human ontogenesis. Investigation of prenatal development of human structures of intercostal spaces (IS) in a chronological sequence allows to establish general biological laws of morphogenesis of the skeleton and muscles of the thorax, neurovascular formations of the IS, variants of

their structure and topography, as well as morphological preconditions of the possible occurrence of congenital malformations of the development of the components of IS, which are formed under the influence of exogenous and endogenous factors in critical periods of fetal life [18]. Taking into account the theoretical and practical importance of anatomical facts about age and individual anatomical variability of IN, such research during the human fetal period is considered topical.

Materials and Methods

The anatomical study of topography of the I–XII IN involved 70 specimens of human fetuses aged 4–10 months, 81–375 mm of crown-rump length (CRL) by means of macromicroscopic preparation, surface staining of dissected vessels and nerves, and morphometry. The IN of the right and left sides were studied along their entire length from the place of origin to the terminal branches in the muscles and the skin of the anterior-lateral parts of the body. In accordance with the peculiarities of branching and form of the links of IN, the internal surface of the thorax was conditionally divided into three sections: dorsal (from the intervertebral openings to the angles of the ribs), the median (from the angles of the ribs to the beginning of their costal cartilages) and ventral (from the beginning of the costal cartilages to the edge of the sternum). Fetus specimens weighing over 500 g were studied directly in the Chernivtsi Regional Children's Pathology and Anatomy Bureau, Ukraine, in accordance with the cooperation agreement. Specimens of fetuses from the Museum of the Department of Human Anatomy named after M. H. Turkevych and the Department of Histology, Cytology and Embryology of Bukovinian State Medical University, Chernivtsi, Ukraine, were also involved in the study [19]. The research was carried out in compliance with the basic bioethical provisions of the Council of Europe Convention on Human Rights and Biomedicine (dated 04.04.1997), the Helsinki Declaration of the World Medical Association on the Ethical Principles of Scientific Medical Research with Human Participation (1964–2013), the Order of the Ministry of Health of Ukraine № 690 (dated September 23, 2009), and taking into account the methodological recommendations of the Ministry of Health of Ukraine "Procedure for extracting biological objects from dead persons whose bodies are subject to forensic examination and pathological anatomical research, for scientific purposes" (2018) [20]. The Commission on Biomedical Ethics of Bukovinian State Medical University has not revealed any violations of bioethical and moral norms during the scientific study.

Results

In the majority (65) of examined fetuses, the anterior branch of the first thoracic spinal nerve or the I IN forms part of the brachial plexus and only in rare observations it gives off a thin trunk that goes in the first IS along the internal surface of the internal intercostal muscle (Figure 1).

The I IN from the side of the internal surface of the thorax is covered with endothoracic fascia and parietal pleura. On the way to the sternum from the I IN there arise 2–4 thin branches that pass to the internal intercostal muscle and to the periosteum of the I rib, and in the middle of the length of the I rib the I IN is divided into the superior and inferior branches. The superior branch of the I IN goes to the edge of the sternum and is located in the front of the parasternal neurovascular bundle. The links between the superior branch of the I IN with parasternal nerve were also detected. The superior branch of the I IN, passing between the muscle bundles of the internal intercostal muscle and the pectoralis major at the edge of the sternum, gives off 3–5 thin branches to the skin of the sternal region. In rare cases, 1–2 skin branches reach the level of connection of the costal cartilage of the III rib with the sternum. The inferior branch of the I IN branches out in the thickness of the internal intercostal muscle. In the region of the superior edge of the cartilage of the II rib, one of the branches is connected to the ascending nerve trunk of the II IN. Consequently, the superior branch of the I IN is branched out in the skin and vessels, and its inferior branch – exclusively in the muscle.

The anterior branches of the II–VII spinal nerves (II–VII IN) in the dorsal regions of the IS (from the intervertebral openings to the angles of the ribs) from the internal surface of the thorax are covered only with endothoracic fascia and the parietal pleura and are divided into 2–6 nerve trunks. The interim rare connecting branches are found in these regions between the adjacent IN. There are also links between the I and II, II and III IN, in the formation of which several branches take part.

From the angles of the ribs and to the level of the middle axillary line (middle section), IN are usually placed along the inferior edges of the ribs between the muscle bundles of the internal intercostal muscles. Only in the fetus of 250 mm of CRL, the V right IN and in the fetus of 310 mm of CRL, the VI left IN were directed to the front of the angle of the V and VI ribs along 12 and 25 mm, respectively, between the internal and external intercostal muscles, and then went into the thickness of the internal intercostal muscle. The numerous muscle branches to the intercostal muscles is a characteristic feature of the IN branching in their middle section. In the middle of the length of the bony part of the ribs or at the level of the middle axillary line, the II–VII IN predominantly branch out into two identical branches of the same diameter – anterior and lateral musculocutaneous branches. The anterior musculocutaneous branches are a direct extension of the IN, directed to the anterior end of the bony part of the corresponding ribs along their inferior edge or along the internal surface of the internal intercostal muscles, or in the thickness of the latter. At the distance of 5–11 mm of the anterior ends of the bony parts of the ribs, the anterior musculocutaneous branches of the II–VII IN are placed on the internal surface of the internal intercostal muscles and covered from the side of the internal surface of the thorax with endothoracic fascia and parietal pleura. Starting from the places of joint of the anterior ends of the bony parts of the ribs with the costal cartilages and to the edge of the sternum, the anterior musculocutaneous branches of the II–VII IN pass between the muscular or

tendinous bundles of the transverse thoracic muscle, on one side, and the internal intercostal muscles – on the other side. In this segment, these branches branch out into 2–4 trunks, which are interconnected by thin branches (Figure 2). It should be noted that the number of connecting branches between adjacent IN increases in the craniocaudal direction. Adjacent IN are predominantly joined by rare trunks, which intersect the internal surface of the ribs; the formation of intermediate trunks occurs rarely. The latter arise both from the trunks of the IN, and, in some cases, from the connecting branches between the adjacent IN, are placed under the parietal pleura, and are characteristic for the superior IN, usually for the III–V IN.

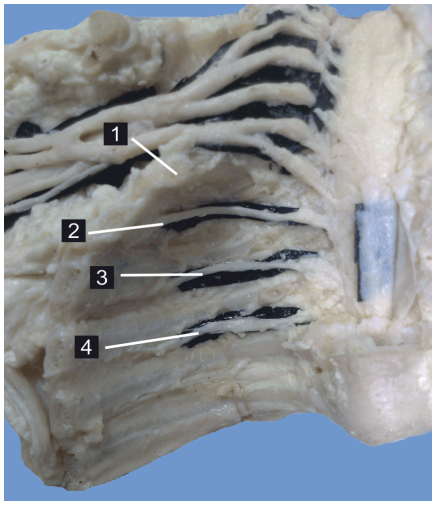

Figure 1 – ***The right half of the thoracic cavity (inside view) in the fetus of 330 mm of CRL. Macrospecimen (×3.5). 1: The first rib; 2: Intercostal nerve of the first intercostal space; 3: Intercostal nerve of the second intercostal space; 4: Intercostal nerve of the third intercostal space. CRL: Crown-rump length.***

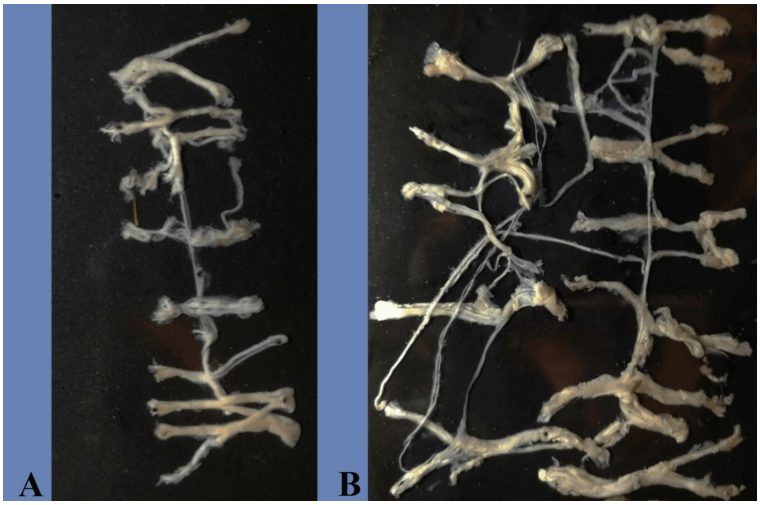

Figure 2 – ***Highlighted II–VII intercostal nerves in fetuses of different ages: (A) In the fetus of 130 mm of CRL (×4.8); (B) In the fetus of 165 mm of CRL (×5.2). CRL: Crown-rump length.***

It should be noted that the anterior musculocutaneous branches of the II–VII IN pass to the front of the parasternal neurovascular bundle and by means of connecting branches are interconnected with each other, with the parasternal nerve or with the nerve plexus of the internal thoracic artery. These links are found on the internal surface of the anterior ends of the bony parts of the II–VII ribs or their costal cartilage. Rare thin branches pass from the anterior musculocutaneous branches of the II–VI IN to the transverse thoracic muscle. In the region of the sternum edge, the anterior musculocutaneous branches penetrate through the internal intercostal muscles and the tendinous bundles of the pectoralis major into a small layer of subcutaneous adipose tissue and provide the innervations of the skin of the anterior regions of the thorax. The lateral musculocutaneous branches of the II–IV IN are distributed in the thickness of the external intercostal muscles and in the skin of the lateral regions of the thorax. Lateral musculocutaneous branches of the V–VII IN enter the superior section of the external abdominal oblique muscle, and also give off branches to the skin of the lateral region of the thorax.

Inferior IN (VIII–XII) pass inside the IS and branch out into 2–6 thinnest branches (Figure 3). Between the IN of the adjacent IS there occur non-continuous rare connecting branches. In particular, the connecting branches between the VIII and IX IN, between the IX and X IN on the left were found in the fetus of 280 mm of CRL (Figure 4). To the front from the angles of the ribs, the inferior IN are placed between the muscle bundles of the internal intercostal muscles. In the examined fetuses, the XI IN passes along the inferior edge of the XI ribs along the internal surface of the internal intercostal muscle, and the subcostal nerve – along the internal surface of the *quadratus lumborum* muscle, slightly below the XII rib.

After passing through the muscle bundles of the diaphragm, the VIII–XII IN are divided into the lateral and anterior cutaneous, abdominal and muscular branches, or lateral and anterior musculocutaneous branches. The lateral musculocutaneous branches of the inferior IN branch out in the thickness of the external abdominal oblique muscle of the abdomen and in the skin of the lateral region of the abdomen. It should be noted that the direction of the lateral musculocutaneous branches of the inferior IN does not coincide with the direction of the muscle bundles of the external abdominal oblique muscle. In this case, the lateral musculocutaneous branches of IN cross the muscle bundles above the indicated muscle at an acute angle of 15–20°. The anterior musculocutaneous branches of the inferior IN are located between the transverse and internal abdominal oblique muscles and reach the lateral edge of the *rectus abdominis* muscle, providing the innervations of the latter, as well as the innervation of the skin of the anterior region of the abdomen. It should be noted that the anterior musculocutaneous branches of the VII–IX IN are placed between the aponeurosis of the internal abdominal oblique muscle

and the muscle bundles of the transverse abdominal muscle. The direction of the anterior musculocutaneous branches of the VII and VIII IN coincides with the direction of the costal cartilages of the corresponding ribs, and the anterior musculocutaneous branch of the IX IN runs parallel to the bundles of the transverse abdominal muscle. The anterior musculocutaneous branches of the XI and XII IN have a descending direction and are placed between the muscle bundles of the transverse and internal abdominal oblique muscles.

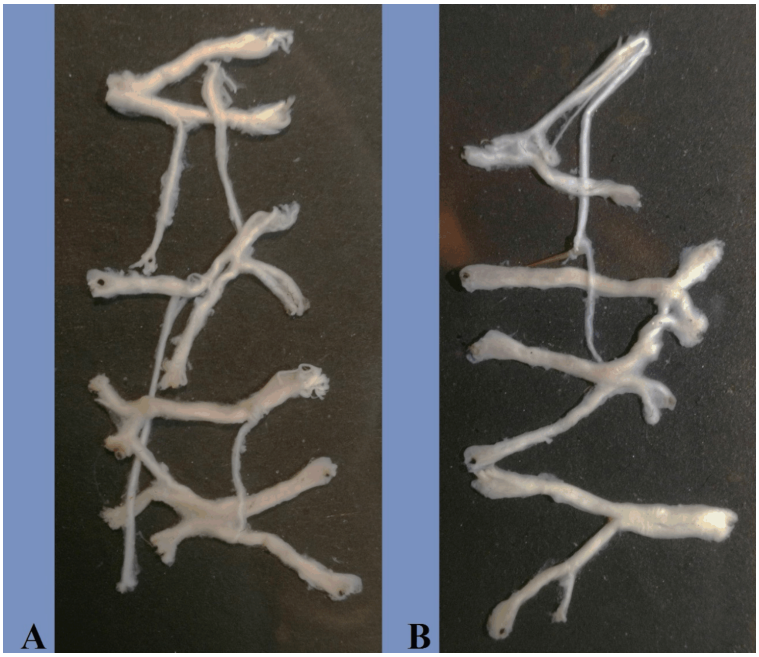

Figure 3 – ***Highlighted VIII–XII intercostal nerves in fetuses of different ages: (A) In the fetus of 315 mm of CRL (×5.2); (B) In the fetus of 365 mm of CRL (×4.7). CRL: Crown-rump length.***

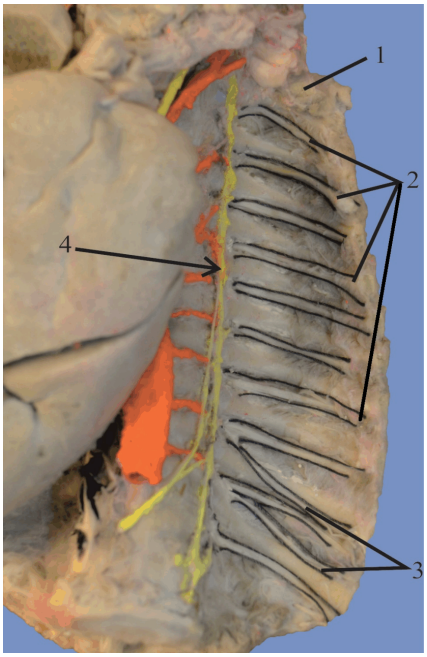

Figure 4 – ***The left half of the thoracic cavity (inside view) in the fetus of 280 mm of CRL. Macrospecimen (×2.4). 1: The first rib; 2: Intercostal nerves; 3: Connecting branches between adjacent intercostal nerves; 4: Thoracic section of the sympathetic trunk. CRL: Crown-rump length.***

It should be noted that connecting branches various in shape and arrangement are detected on the internal surface of the thorax between the adjacent IN and the collateral branches. Connective branches were also found in the region of the anterior-lateral parts of the abdominal wall between the anterior and lateral musculocutaneous branches of the IN (Figure 5). The VII–XII IN gives off the thinnest nerve branches that penetrate the thickness of the muscular part of the diaphragm. The connecting branches go from the lateral edge or the posterior periphery of the nodes of the thoracic section of the sympathetic trunk to the IN. Interestingly, connecting branches can join not only the IN, which is located at the level of this node, but also to the IN located above and below (Figures 6 and 7).

It was revealed that each rib usually receives numerous branches from at least two adjacent IN: located higher and lower. In this case, more branches to the rib arise from the above located IN than from the below located IN. From the above located IN, the costal branches go to the superior edge, the internal and external surfaces of the rib, and the costal branches from the below located IN go to the inferior edge, the internal and external surfaces of the rib. Branches from the I and II IN, which branch out along the superior and inferior surfaces of the rib go to the I rib. It was also noted that the connecting branches between the adjacent IN also give off rare costal branches. The costal branches from the IN are distributed along the entire length of the bony part of the rib and costal cartilage. In this case, most of the costal branches from the IN go to the posterior third of the rib, and less go to its anterior third. The costal cartilages, depending on the level of their location, are on the average innervated by 7–18 branches, which predominantly arise from the adjacent IN, plexuses of the intercostal and internal thoracic vessels, rarely – from the brachial plexus. From two to four branches usually go from the I IN to the manubrium of the sternum and 1–3 branches pass to its body. 3–14 branches arise from the II–V IN to the body of the sternum from each side, and 1–2 branches pass from the VI IN to the xiphoid process of the sternum.

Our study of fetal anatomy of IN resulted in identifying the asymmetry of the topography of the IN and their branches on the right and on the left in the fetuses of different and the same age groups, and even in the same fetus. Examination of the fetus of 225 mm of CRL revealed anatomical variability of certain IN both on the right and on the left. In particular, the right II IN along its greater length is located in the costal sulcus, stretching along the whole body of the rib. 6.5 mm before the place of transformation of the bony part of the II rib into the costal cartilage, the right II IN was divided into two branches: the superior, which was a continuation of the trunk of the IN and was located along the inferior edge of the II rib,

and the inferior branch, which passed in the oblique caudal direction to the costal cartilage of the III rib and was located between the muscle bundles of the internal intercostal muscle. At first, the right III IN (from the level of the head to the neck of the rib) was located along the inferior edge of the third rib, and then was divided into the superior and inferior branches. The latter was parallel to the superior edge of the IV rib, without reaching the angle of this rib, then it crossed the internal surface of the body of the IV rib, formed a loop and reached the superior edge of the body of the V rib. The superior branch of the III IN was placed in the sulcus of the III rib, and at the level of the middle part of the bony part of this rib it gave off a branch that, in the craniolateral direction, crossed the internal surface of the body of the III rib, located along the superior edge of the body of the III rib up to its costal cartilage. The right VI IN from the head to the angle of the rib was placed in the sulcus of the rib, then it was divided into two branches: the superior one, which crossed the internal surface of the VI rib in the oblique cranial direction, and passed along the superior edge of the rib to the level of the costal cartilage. The inferior branch of the VI IN, along its greater length, passed along the superior edge of the body of the VII rib, without reaching the anterior end of the latter, turned to the top and reached the point of the transformation of the bony part of the VI rib into its costal cartilage. The right VIII IN at the level of the transition of the neck into the body of the rib was branched out into two branches: the superior one lying in the sulcus of the VIII rib, and the inferior one, which was initially parallel to the superior branch, passing then in the oblique cranial direction upward to the superior edge of the IX rib, placed between the muscle bundles of the internal intercostal muscle. The right X IN at the level of the neck of the X rib was divided into two branches: the superior one, located along the inferior edge of the X rib, and the inferior one, passing in the oblique cranial direction upward to the superior edge of the XI rib entering into the thickness of the internal intercostal muscle. The right subcostal nerve passed along the internal surface of the *quadratus lumborum* muscle, somewhat below the XII rib (Figure 8A). This examined fetus was characterized by the left II IN located in the middle of the IS between the muscle bundles of the internal intercostal muscle. The left III IN at the level of the transition of the head into the neck of the rib was branched out into two branches: the superior, which was a continuation of the trunk of the nerve and was lying into the sulcus of the third rib, and the inferior branch, which was directed obliquely, downward and laterally to the superior edge of the body of the IV rib. Thin connecting branch was detected between the superior and inferior branches of the III IN. Two connecting branches were also detected between the left V and VI IN. From the left V IN, at the level of the head of the V rib, the first connecting branch was arising, passing in the oblique cranial direction along the internal surface of the internal intercostal muscle and at the level of transition of the neck of the VI rib into the body of the rib joined the VI IN. Another connecting branch connected V and VI IN somewhat laterally from the angles of the corresponding ribs. The left VII IN at the level of the angle of the VII rib branched out into two branches: the superior one, lying into the sulcus of the VII ribs and the inferior one, passing parallel to the superior branch along the superior edge of the body of the VIII rib (Figure 8B).

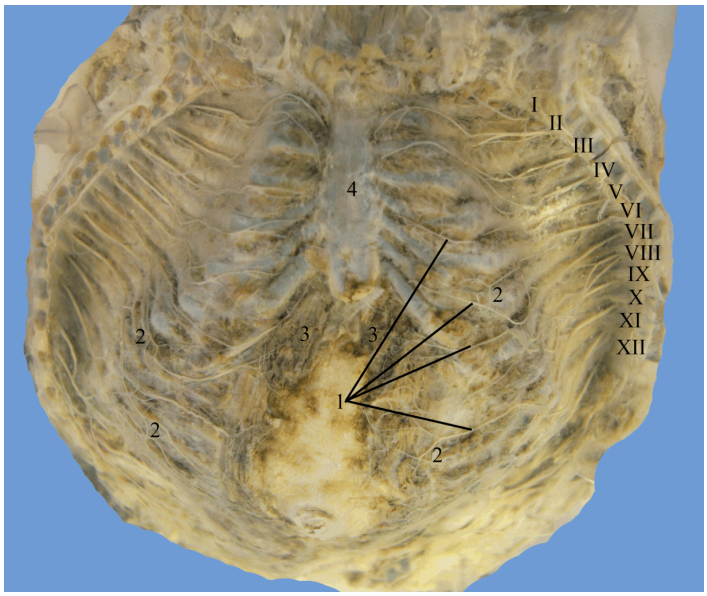

Figure 5 – ***Branching and links of the intercostal nerves (I–XII) and their anterior musculocutaneous branches on the internal surface of the thoracic and abdominal walls in the fetus of 370 mm of CRL. Macrospecimen (×2.1). 1: Anterior musculocutaneous branches; 2: Connecting branches; 3: Rectus abdominis muscle; 4: Sternum. CRL: Crown-rump length.***

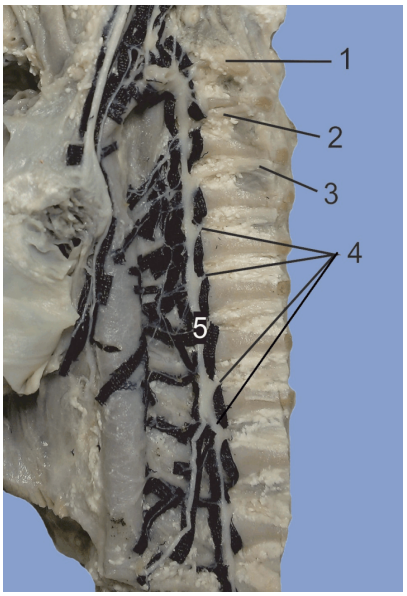

Figure 6 – ***The left half of the thoracic cavity (inside view) in the fetus of 240 mm of CRL. Macrospecimen (×2.4). 1: The first rib; 2: Intercostal nerve of the second intercostal space; 3: Intercostal artery of the third intercostal space; 4: Connecting branches of nodes of the thoracic section of the sympathetic trunk to the intercostal nerves; 5: Thoracic section of the sympathetic trunk. CRL: Crown-rump length.***

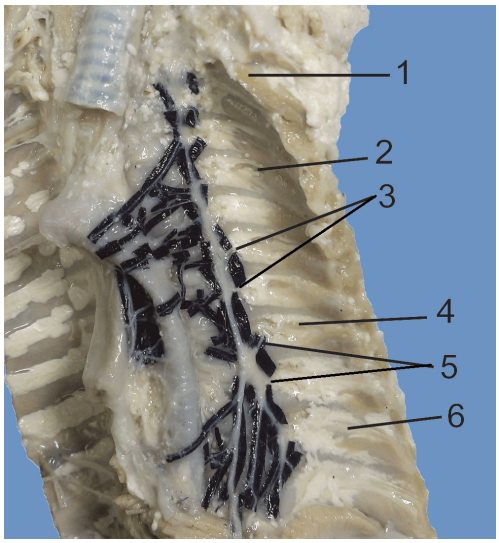

Figure 7 – ***The left half of the thoracic cavity (inside view) in the fetus of 185 mm of CRL. Macrospecimen (×2.6). 1: The first rib; 2: Intercostal nerve of the third intercostal space; 3: Connecting branches from the thoracic node of the sympathetic trunk to the V and VI intercostal nerves; 4: Intercostal nerve of the seventh intercostal space; 5: Connecting branches from the thoracic node of the sympathetic trunk to the VII and VIII intercostal nerves; 6: Intercostal nerve of the ninth intercostal space. CRL: Crown-rump length.***

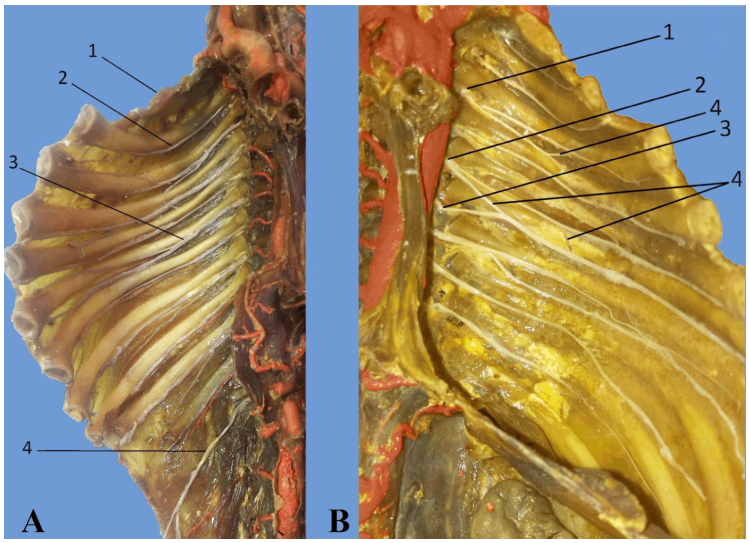

Figure 8 – ***Right (A) and left (B) half of the thoracic cavity (inside view) in the fetus of 225 mm of CRL. Macrospecimen: (A) ×2.1; (B)×3.4. (A) 1: The first rib; 2: Intercostal nerve of the second intercostal space; 3: Intercostal nerve of the sixth intercostal space; 4: Right subcostal nerve. (B) 1: Intercostal nerve of the third intercostal space; 2: Intercostal nerve of the fifth intercostal space; 3: Intercostal nerve of the sixth intercostal space; 4: Connecting branches. CRL: Crown-rump length.***

Discussions

Data on the topography of IN in adults are described in detail in various sources [21–23]. It is known that IN are located in the IS between the internal and the deepest intercostal muscles. At the same time, there is a lack of data on the peculiarities of the formation and topography of IN in the prenatal period of human development, though there are some literary sources pointing to the similarity of the location of IN in the postnatal period of ontogenesis [24–26].

The results of our research on the fetal topography of IN are consistent with these isolated data regarding the topographic and anatomical peculiarities of IN in the prenatal period of ontogenesis, as well as with information on topographic anatomy of IN in adults [21–23]. Thus, the IN trunk in human fetuses is not located along the whole continuation of IS, it only reaches its middle part. Its anterior musculocutaneous branch passes in the rest of the IS and on the abdominal wall. In the middle section of the internal surface of the thorax (from the angles of the ribs to the beginning of the costal cartilages), IN usually pass in the thickness of the internal intercostal muscles. In this section from the IN, especially from the III to the IX IN, diverse is shape connecting branches arise which connect adjacent IN, and circumflex branches, variable in number and topography. The number of connecting branches between adjacent IN in the ventral section of the internal surface of the thorax increases from the top to the bottom and exceeds their number in the dorsal division of the internal surface of the thorax. Each rib receives branches from at least two adjacent IN. The branches of the six superior IN participate in the innervations of the parts of the sternum. Other researchers also found numerous connecting branches, linking different IN, and also nodes of the thoracic part of the sympathetic trunk in the prenatal period of human ontogenesis [27, 28]. These complex connections between the nerve structures should be taken into account by surgeons when performing sympathectomy [28].

At the same time, the study revealed a significant variability of the topography and asymmetry of the trunks of the IN and their branches. Each IN is characterized by its topographic-anatomical peculiarities. In particular, it has been found that the branches of the I IN in human fetus are distributed in different ways: its superior branch is in the skin and vessels, and the inferior one is exclusively in the thickness of the internal intercostal muscle.

The anterior musculocutaneous branches of the II–VII IN have constant links between them and with the nerve plexus of the internal thoracic artery. Numerous and various in their shape links were detected between the anterior and lateral musculocutaneous branches of the IN in the area of the anterior-lateral regions of the abdominal wall. The direction of the lateral musculocutaneous branches of the inferior IN does not coincide with the direction of the muscle bundles of the external abdominal oblique muscle. The received data about the fetal anatomical variability of IN do not coincide with existing perceptions about their segmental structure and may, to some extent, be explained by the presence of numerous bonds between different IN, as indicated above. The similar variability and asymmetry of the IN distribution is not described in

the studies conducted on human fetuses. There are only rare studies that indicate the variability and asymmetry of IN topography in adults, with the presence of sexual differences in variants of IN penetration into the abdominal muscle [2, 29, 30]. In addition, our studies confirm the assumptions made regarding embryological preconditions [31] for the development of variability and contradictions that exist in dermatome maps [32, 33].

Data on fetal topography of the II–VII IN, the form of links between IN and the variability of their branches in the IS make it possible to anatomically substantiate surgical interventions in the area of the thorax and to determine the possibilities of compensatory innervation of the internal surface of the thorax. Information on the location of the branches of the IN in the area of the anterior regions of the abdomen will help clinicians to make decisions on the shape and direction of the incisions in different parts of the abdominal wall, which is important in preventing the occurrence of postoperative chronic pain syndromes and hypo- and paresthesias [34, 35]. At the same time, the study confirms the need for further elucidation of the microscopic structure of IN in human fetuses and newborns.

Conclusions

Branches of the I IN are functionally different, because the superior one is branching out in the skin and blood vessels, and the inferior branch – in the strata of the internal intercostal muscle. Age and individual anatomical variability of the IN and their musculocutaneous branches in human fetuses has been established. The anterior musculocutaneous branches of the II–VII IN pass to the front of the parasternal neurovascular bundle and by means of connecting branches are linked with each other, with parasternal nerve or nerve plexus of the internal thoracic artery. Trunks of the adjacent IN are interconnected by means of connecting branches, with numerous links, diverse in shape, observed between the anterior and lateral musculocutaneous branches of the VIII–XII IN in the area of the anterior-lateral parts of the abdominal wall. The connecting branches pass from the nodes of the thoracic region of the sympathetic trunk to the IN.

Compliance with ethics requirements

The authors declare no conflict of interest regarding this article.

The authors declare that all the procedures and experiments of this study respect the ethical standards in the Helsinki Declaration of 1964, as revised in 2013, as well as the national law.

No funding for this study.

References

[1] van der Graaf T, Verhagen PC, Kerver AL, Kleinrensink GJ. Surgical anatomy of the 10th and 11th intercostal, and subcostal nerves: prevention of damage during lumbotomy. J Urol, 2011, 186(2):579–583.

[2] Mol FMU, Lataster A, Scheltinga M, Roumen R. Anatomy of abdominal anterior cutaneous intercostal nerves with respect to the pathophysiology of anterior cutaneous nerve entrapment syndrome (ACNES): a case study. Transl Res Anat, 2017, 8–9:6–10.

[3] Chernyh AV, Zakurdaev EI, Zakurdaeva MP. To the question of intercostal nerve injury prevention at the posterior separation hernioplasty of umbilical hernias. Novosti Khirurgii, 2016, 24(3):234–239 (in Russian).

[4] Chernyh AV, Zakurdaev EI, Yakusheva NV, Vitchinkin VG, Zakurdaeva MP, Belov EV. Clinical features of the topographic anatomy of the intercostal nerves in the umbilical region of the anterior abdominal wall. Crimea J Exp Clin Med, 2016, 6(3):126–131 (in Russian).

[5] Ellis H. The ribs and intercostal spaces. Anaesth Intensive Care Med, 2008, 9(12):518–519.

[6] Oram R, Rasburn N. Analgesia for thoracic surgery. Anaesth Intensive Care Med, 2017, 18(12):606–608.

[7] Simpson W. Anaesthesia for thoracic surgery. Anaesth Intensive Care Med, 2017, 18(12):593–597.

[8] García-Tirado J, Rieger-Reyes C. Suture techniques of the intercostal space in thoracotomy and their relationship with post-thoracotomy pain: a systematic review. Arch Bronconeumol, 2012, 48(1):22–28.

[9] Khalil AE, Abdallah NM, Bashandy GM, Kaddah TA. Ultrasound-guided serratus anterior plane block *versus* thoracic epidural analgesia for thoracotomy pain. J Cardiothorac Vasc Anesth, 2017, 31(1):152–158.

[10] Asfazadourian H, Tramond B, Dauge MC, Oberlin C. Morphometric study of the upper intercostal nerves: practical application for neurotisations in traumatic brachial plexus palsies. Ann Chir Main Membre Sup, 1999, 18(4):243–253.

[11] Flake AW. Surgery in the human fetus: the future. J Physiol, 2003, 547(Pt 1):45–51.

[12] Antsaklis A. Fetal surgery: new developments. Ultrasound Rev Obstet Gynecol, 2004, 4(4):245–251.

[13] Adzick NS. Prospects for fetal surgery. Early Hum Dev, 2013, 89(11):881–886.

[14] Pedreira DAL. Advances in fetal surgery. Einstein (São Paulo), 2016, 14(1):110–112.

[15] Moron AF, Barbosa MM, Milani HJF, Sarmento SG, Santana EFM, Suriano IC, Dastoli PA, Cavalheiro S. Perinatal outcomes after open fetal surgery for myelomeningocele repair: a retrospective cohort study. BJOG, 2018, 125(10):1280–1286.

[16] Van der Veeken L, Russo FM, De Catte LD, Gratacos E, Benachi A, Ville Y, Nicolaides K, Berg C, Gardener G, Persico N, Bagolan P, Ryan G, Belfort MA, Deprest J. Fetoscopic endoluminal tracheal occlusion and reestablishment of fetal airways for congenital diaphragmatic hernia. Gynecol Surg, 2018, 15(1):9.

[17] Zheleznov LM, Galeeva EN, Lisitskaya SV, Lyashchenko DN, Mikhailov SN, Popova RA. Fetal topographical anatomy – applied and theoretical significance. Morfologiya, 2006, 129(4):51 (in Russian).

[18] Khmara TV, Okrim II, Ryznychuk MO, Zamorskii II, Rak OM. Morphometric study of the skeleton of the thorax in human fetuses aged 7–10 months. Arch Balk Med Union, 2018, 53(4):497–505.

[19] Khmara TV, Ryznychuk MA. Age-related and individual anatomical variation in testicular topography in human fetuses. Russ J Dev Biol, 2018, 49(4):234–239.

[20] Mishalov VD, Voichenko VV, Malysheva TA, Dibrova VA, Kuzyk PV, Yurchenko VT. The procedure for the removal of biological objects for scientific purposes from deceased persons, whose bodies are subject to forensic examination and pathoanatomical research. Osvita Ukrainy, 2018, (2):3–13 (in Ukrainian).

[21] Standring S (ed). Gray's anatomy: the anatomical basis of clinical practice. 41st edition, Elsevier Ltd., Philadelphia, 2016, 944–945.

[22] Hansen JT. Netter's clinical anatomy. 4th edition, Elsevier Inc., Philadelphia, 2019, 98–100.

[23] Abrahams PH, Spratt JD, Loukas M, van Schoor AN. McMinn's & Abrahams' clinical atlas of human anatomy. 7th edition, Elsevier–Mosby, 2014, 209–210.

[24] Davies F, Gladstone RJ, Stibbe EP. The anatomy of the intercostal nerves. J Anat, 1932, 66(Pt 3):323–333.

[25] Cave AJE. The distribution of the first intercostal nerve and its relation to the first rib. J Anat, 1929, 63(Pt 3):367–379.

[26] Hesselmans LFGM, Jennekens FGI, Van den Oord CJM, Veldman H, Vincent A. Development of innervation of skeletal muscle fibers in man: relation to acetylcholine receptors. Anat Rec, 1993, 236(3):553–562.

[27] Baljet B, Boekelaar AB, Groen GJ. Retroperitoneal paraganglia and the peripheral autonomic nervous system in the human fetus. Acta Morphol Neerl Scand, 1985, 23(2):137–149.

[28] Groen GJ, Baljet B, Boekelaar AB, Drukker J. Branches of the thoracic sympathetic trunk in the human fetus. Anat Embryol (Berl), 1987, 176(4):401–411.
[29] Chernyh AV, Zakurdaev EI, Zakurdaeva MP. New data on surgical anatomy of intercostal nerves in mesogastric region of abdominal wall. Kursk Scientific and Practical Bulletin "Man and His Health", 2016, (2):96–99 (in Russian).
[30] Tubbs RS, Shoja MM, Loukas M (eds). Bergman's comprehensive encyclopedia of human anatomic variation. John Wiley & Sons, Hoboken, NJ, 2016, 357–360.
[31] Ladak A, Tubbs RS, Spinner RJ. Mapping sensory nerve communications between peripheral nerve territories. Clin Anat, 2014, 27(5):681–690.
[32] Lee MW, McPhee RW, Stringer MD. An evidence-based approach to human dermatomes. Clin Anat, 2008, 21(5): 363–373.
[33] Apok V, Gurusinghe NT, Mitchell JD, Emsley HC. Dermatomes and dogma. Pract Neurol, 2011, 11(2):100–105.
[34] Ellis H, Colborn GL, Skandalakis JE. Surgical embryology and anatomy of the breast and its related anatomic structures. Surg Clin North Am, 1993, 73(4):611–632.
[35] Lopez ME, Olutoye OO. Breast embryology, anatomy, and physiology. In: Ledbetter DJ, Johnson PRV (eds). Endocrine surgery in children. Springer, Berlin–Heidelberg, 2018, 365–376.

Corresponding author
Tatyana Vladimirovna Khmara, Professor, DSc, MD, PhD, Department of Human Anatomy named after M. H. Turkevych, Bukovinian State Medical University, 2 Theatralna Square, 58002 Chernivtsi, Ukraine; Phone +380661179366, e-mail: khmara.tv.6@gmail.com

Received: January 29, 2019

Accepted: August 13, 2019