

Complications related to breast reconstruction after mastectomy using multiple surgical techniques – a national and international comparative analysis

SILVIU-ADRIAN MARINESCU¹⁾, CĂTĂLIN-GHEORGHE BEJINARIU¹⁾, ELENA ȘAPTE²⁾,
 MARIUS CRISTIAN MARINAȘ³⁾, CARMEN GIUGLEA⁴⁾

¹⁾Department of Plastic and Reconstructive Surgery, "Bagdasar-Arseni" Emergency Clinical Hospital, Bucharest, Romania

²⁾Department of Anatomy, Faculty of Dental Medicine, "Ovidius" University of Constanța, Romania

³⁾Department of Anatomy, University of Medicine and Pharmacy of Craiova, Romania

⁴⁾Department of Plastic and Reconstructive Surgery, "St. John" Emergency Clinical Hospital, Bucharest, Romania

Abstract

The present paper describes and analyzes complications related to alloplastic breast reconstruction, as well as those associated with surgical techniques involving myocutaneous flaps. The article also contains a comparative analysis of the results obtained with the data in the international specialized literature. The statistical analysis is primary based on data obtained from patients included in the *National Breast Reconstruction Program* developed within the "Bagdasar-Arseni" Emergency Clinical Hospital, Bucharest, Romania, between 2015 and 2019. In order to highlight and present a thorough comparison between the possible long-term complications associated with multiple reconstructive techniques, the paper also includes data related to patients who have undergone such surgical interventions in the aforementioned Health Unit, but which were not included in the national program, resulting a total of 73 reconstructive surgical interventions. The research results show that the overall rate of complications was 43.83%, skin necrosis, superficial infection and seroma being in this order the main complications that were identified. In the authors' opinion, risks of complications are moderated in relation with breast reconstruction surgery. However, the complication rate significantly varies depending on the chosen technique. The lowest risk levels registered in this study were associated with the breast reconstruction using the two-stage expander-implant technique. The analysis compares the achieved results with data provided by international studies, the main differences being caused by the status of the medical infrastructure, as well as the moment of hospital admission that is primarily determined by the level of medical education.

Keywords: breast reconstruction, surgical complications, expander-implant technique, TRAM flap, DIEP flap.

Introduction

The worldwide increasing incidence of breast cancer [1–3], innovation related to the development of new screening systems, as well as improving the patients' know-how related to medical education have significantly contributed to the increase in the number of requests for reconstructive surgery [4, 5]. Highlighting the benefits of breast reconstruction on the psychological profile of patients was also a reason that has increased the popularity of the related surgical techniques [6]. An ascending trend can also be observed in Romania in relation with performing breast reconstruction; however, the overall growth rate is lower than the average international one. The authors place this on account of the patients' limited access to education and specialized medical services, especially in the rural area, as well as the lack of efficient screening programs that identify patients at risk in the early and intermediate stages of the disease that allow breast reconstruction as an option. The importance of this phenomenon is due to the fact that breast cancer constitutes one of the most common malignant pathologies that affects the female population, also associating an increased mortality rate in case of late detection [7]. Effective communication referring to the associated risks related to mastectomy and to the impact exerted

by the occurrence of complications during the later stages of breast reconstruction is essential in order to avoid psychological imbalances and increase the patients' adherence to treatment [8].

The onset of the *National Breast Reconstruction Program* has created the foundation for the development of a series of scientific materials that have contributed, to the possible extent, to a better understanding of the breast reconstruction protocol and its consequences on the patients' quality of life [9]. The psychological impact of breast reconstruction can be devastating for patients undergoing surgical procedures for breast cancer, approximately 50% of those suffering from negative self-image and go through significant changes related to their sexuality [10].

The degree of complexity for the breast reconstruction intervention has a great variability due to the many available reconstructive surgical techniques. In theory, the complication rate should depend on the complexity of the surgical procedure. However, the experience of the plastic surgeon involved in the reconstructive intervention, the available medical equipment and infrastructure, as well as the local particularities of the patients are factors that contribute significantly to the number of postoperative complications.

Nowadays, there are a lot of reconstructive techniques and approaches dedicated to the mammary region, the ability to integrate and implement these relying on the experience of the surgical teams involved in the breast reconstruction. Specialized literature is highly focused on the accelerated increase in the number of patients that undergo breast reconstruction surgery, the doubling of this number in a decade [11] being suggestive of the efficiency of the screening programs, improved healthcare infrastructure and increased medical education.

A commonly used technique with a low degree of difficulty compared to reconstructive techniques using myocutaneous flaps [12] is the two-stage reconstruction using the expander-implant association. Although the postoperative outcome does not provide the advantage of the natural aspect provided by flap reconstructions, the short duration of the surgery, the reduced hospitalization time and the absence of comorbidities are the main factors that have a significant influence on the patients' decision related to the chosen reconstructive protocol. However, there are differences that are statistically significant between the unilateral and bilateral breast reconstruction, specialized literature suggesting that the length of hospitalization increases in case of bilateral surgery and the associated complication rate being also about 15% higher [13]. The existence of a low rate of complications in case of unilateral breast reconstruction is yet another reason to consider when choosing the proper breast reconstruction technique. Specialized literature also shows that this technique could represent the optimal solution for breast reconstruction after prophylactic mastectomy, being the most commonly used protocol to solve these cases [14]. Another aspect that has to be analyzed before the procedure is the sensitivity of the mammary region, more specific its reduction after mastectomy [15], followed by almost complete loss of sensitivity after the reconstruction surgery [16]; this aspect is an important factor that has a significant impact on the patients' degree of satisfaction.

Aim

The aim of the study was to determine and present the main complications related to breast reconstruction, in order to bring a contribution to extending the knowledge related to this phenomenon and its implications on the patients' degree of satisfaction.

The objectives of the study were related to data and information processed in order to obtain the following results of general interest:

- the determination of the overall rate of complications;
- the identification of the type and number of specific complications;
- the comparative analysis between the complication ratio at national and international level;
- the evaluation of the complications and their impact on the patients' degree of satisfaction.

Patients, Materials and Methods

The research involves data obtained as a result of 73 surgical interventions performed on patients included in the *National Breast Reconstruction Program*, as well as on those not included in the program that underwent reconstructive surgery in the "Bagdasar-Arseni" Emergency Clinical Hospital, Bucharest, Romania, between June 2015

and January 2019. All subjects included in the study have given their informed, written consent related to performing the research and publishing the study's results. The research was conducted with the consent of the Hospital's Ethics Committee.

In order to carry out the statistical analysis, the study includes complications that have occurred during the surgical interventions, as well as those occurring in the medium and long term.

The research database included information on:

- the type of procedure that have been performed;
- the rate of complications associated with each procedure;
- the type of specific complications and their frequency;
- results gathered and selected at national and international level;
- the degree of patient satisfaction in relation with the postoperative outcome.

The assessment of patient satisfaction was performed by elaborating a subjective evaluation grid related to the postoperative outcome with the minimum value of 1 and the maximum value of 10.

Results

Following the processing of the statistical data, the average complication rate was 43.83%, complications included in this analysis being considered irrespective of the surgical procedure and the context of their occurrence (Table 1).

Table 1 – Comparative analysis between complications related to different types of reconstructive techniques

Type of complication	Type of reconstructive technique		
	Expander-implant technique	TRAM flap	LD flap
Major complications			
Total/partial flap loss	0%	0%	0%
Venous congestion	0%	40%	66.67%
Extrusion	3.28%	0%	0%
Contracture	4.92%	0%	33.33%
<i>Average major complication rate</i>	2.05%	10%	25%
Minor complications			
Superficial infection	9.84%	40%	33.33%
Deep infection	3.28%	20%	0%
Hematoma	3.28%	20%	33.33%
Seroma	8.2%	20%	66.67%
Fat necrosis	0%	20%	33.33%
Dehiscence	6.56%	40%	33.33%
Skin necrosis	21.31%	40%	66.67%
Expander failure	3.28%	0%	0%
<i>Average minor complication rate</i>	6.97%	25%	33.33%
Average No. of patients with complications	39.34%	71.43%	60%

TRAM: Transverse rectus abdominis myocutaneous; LD: Latissimus dorsi.

The rate of postoperative superficial infections was 9.84% in patients with complications who had delayed breast reconstruction using the expander-implant technique, deep infections being observed in 3.28% of the patients included in this group (Figure 1).

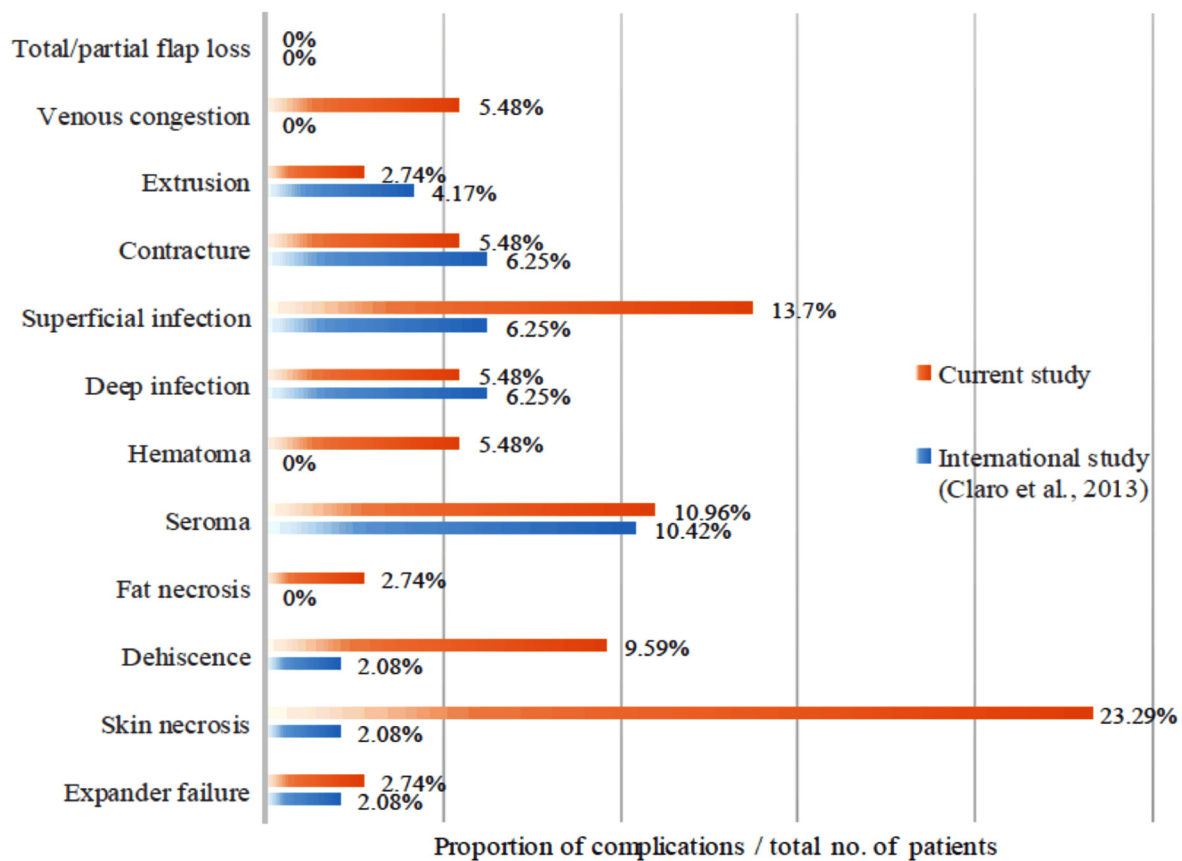


Figure 1 – Ratio of complications encountered during the current study compared to other research results from the specialized literature.

The group of patients who suffered complications after breast reconstruction using the transverse *rectus abdominis myocutaneous* (TRAM) flap technique has had a 60% septic complication rate, especially superficial infections (40%) around the postoperative wounds. Infections localized in the donor area were also associated with other postoperative complications, such as dehiscence and marginal necrosis.

From the group of patients suffering from complications, 33% of those who underwent surgical interventions involving reconstruction using the *latissimus dorsi* (LD) flap have shown superficial infections in the donor areas, 66.67% of them suffering from seromas.

Hematomas were observed in 3.28% of patients with complications after undergoing delayed reconstruction using the expander-implant technique, in 20% of patients who underwent reconstructive surgery using the TRAM flap and 33.33% of patients who had breast reconstruction using the LD flap.

The appearance of seromas was identified in 6.85% of the total number of patients who have chosen breast reconstruction using silicone prostheses and 8.2% of the patients that have suffered postoperative complications. From the group of patients suffering from complications, side effects were observed in 20% of the cases that underwent surgery using the TRAM flap technique and 66.67% of the surgical interventions using the LD flap. The increased proportion of seromas in the last group was caused by the fact that this complication is common in surgical interventions involving the posterior thoracic region, being considered a complication specific to the reconstruction using this technique.

Wound complications, such as dehiscence and marginal necrosis, were observed in 32.88% of the total number of patients and in over 25% of the patients who suffered complications after prosthetic reconstruction; also, from the group of the patients with complications, 80% of the patients who underwent the TRAM protocol and 66.7% of those who underwent reconstruction using the LD flap have had one or both of the above-mentioned complications. The increased percentage in the last two groups is considered to be caused by the high complexity of the techniques, the local particularities of the cases and the associated comorbidities related to these procedures. These complications have been primarily identified in the donor areas. However, additional studies are needed on larger batches in order to have an improved perspective on the proportion of complications that may occur.

In terms of patients suffering from complications related to expander defects or incorrect manipulation of the prosthetic material, the complication rate was 3.28%, this value being determined by malfunctions at the level of the expander's injection site.

Capsular contracture was noted in 4.92% of the cases that suffered complications related to the delayed reconstruction using expander and implant and in 33.33% of cases where the reconstruction was performed by associating the implant with LD flap. Considering that a significant proportion of the patients included in the study have undergone reconstruction surgery within the *National Mammary Reconstruction Program* and that this Project started in 2015, the authors predict that the capsular contraction rate will increase over the next few years among patients who were included in the study.

The analysis of patients' degree of satisfaction related to the results of the reconstructive surgery shows that the highest satisfaction rate was achieved in patients who have chosen the TRAM flap reconstruction technique (average grade: 8.92), the next position being occupied by the LD flap reconstruction with an average grade of 8.75, as for the alloplastic reconstruction the average

grade being 8.25 (Figure 2). The results are based on the fact that the natural aspect achieved by reconstruction with myocutaneous flaps is hardly obtained by using silicone implants. Also, the number of patients who have chosen alloplastic reconstruction was significantly higher compared to the other groups, this being another element that has influenced this report.

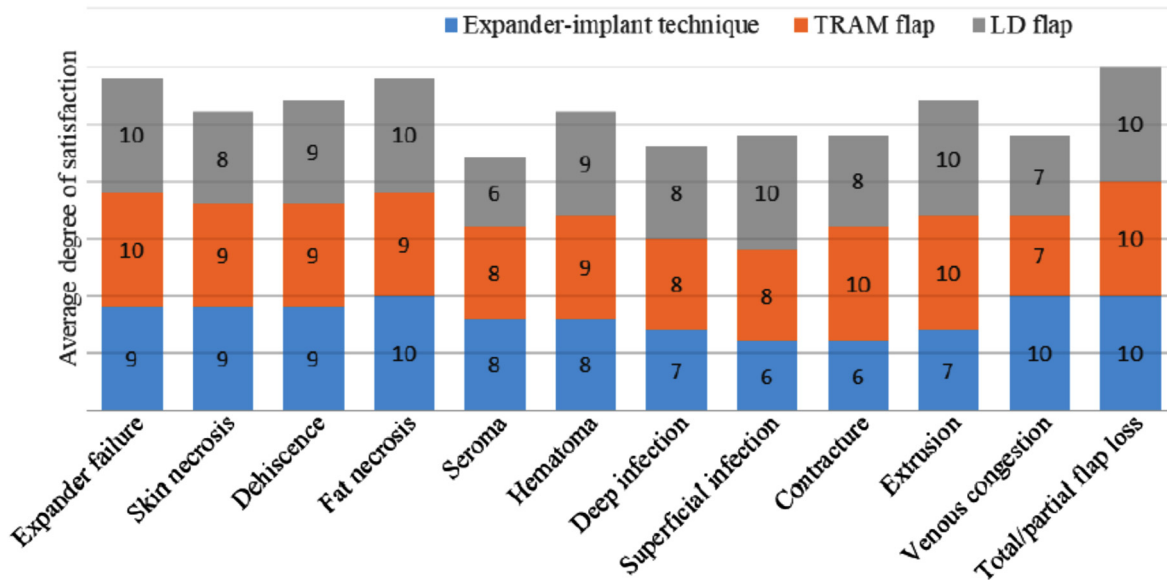


Figure 2 – Average degree of satisfaction in relation with the encountered complications related to multiple reconstructive techniques. TRAM: Transverse rectus abdominis myocutaneous; LD: Latissimus dorsi.

The results of the statistical analysis were strongly influenced by the increased proportion of patients who have chosen delayed reconstruction using the expander-implant technique, therefore additional research is needed on larger batches of patients in which the proportion of the different types of interventions is relatively balanced.

Discussions

Breast reconstruction is, without a doubt, a subject of interest for the international scientific community. Increasing the efficiency of the screening systems has resulted in the detection of breast neoplasms in early and intermediate stages, thus accelerating the development of oncoplastic surgery. The implementation of these principles related to early diagnosis and treatment is difficult in developing countries in which healthcare infrastructure is deficient, therefore the comparative analysis of the research results is highly important, providing information related to the latest surgical techniques and their implementation in the current medical system [5, 17, 18].

Breast reconstruction aims to regain the physiological and anatomical features of the mammary region [19, 20]. In this respect, the reconstructive protocol must be designed so that the distance between the areola and the incision of the sternum is between 19 cm and 21 cm. Regarding the projection and the ptosis degree of the rebuilt breast, the main reference is the distance between the areola and the inframammary fold, the success of the reconstruction being guaranteed by obtaining the same natural appearance, including this value in the range of 5–7 cm. Another important aspect in terms of morphology of the breast region after the reconstruction is the observation of the physiological anatomical structures especially the distance

between the areola and the median line [21]. In this sense, the purpose of the reconstructive intervention is to place this parameter in the range of 9–11 cm [22].

Breast reconstruction using the deep inferior epigastric perforator artery (DIEP) flap technique is considered to be the “gold standard” for autologous tissue plasties [23, 24]. The natural aspect of the reconstructed breast, its ability to naturally modify its morphological characteristics over time and the high level of patient satisfaction are the main advantages of DIEP flap reconstructive technique. Specialized literature shows and experience confirms that contour irregularities occurring in relation with the expander-implant technique are frequent and have a negative impact on patient satisfaction [25]. Several innovative techniques have been proposed in order to solve contour irregularities characteristic of reconstruction techniques using prosthetic materials, such as redistribution of fat tissue from the upper lateral breast region [26], lipofilling and secondary revisions. However, the natural aspect specific to the reconstruction using myocutaneous flaps cannot be achieved. This type of reconstruction is considered to be superior in terms of postoperative results and economically efficient compared to other surgical interventions based on the use of silicone implants [27]. Concerning the incidence of complications, the formation of seromas and hematomas is associated with immediate reconstructions, wound complications being more common in delayed reconstructions [28].

Breast reconstruction using the LD flap is a safe method, the versatility of the flap offering a multitude of opportunities in terms of developing the reconstructive protocol. Although this technique has been widely used over the past 30 years, it has lost popularity over the last

decade in favor of TRAM and DIEP flap reconstructions [29–31].

However, it is a firm therapeutic solution in complicated cases that associate radiotherapy, as well as in those that involve contraindications related to the previously mentioned techniques. The specialized literature includes many materials related to the complications associated with this reconstructive technique, the most frequent of which being the formation of seromas in the donor area [32]. Dorsal hernias, loss of shoulder mobility and scarring are also complications that may occur during the postoperative evolution of these patients [33, 34].

Breast reconstruction using the TRAM flap technique is a commonly used method whose results are confirmed over time [35]. The postoperative complication specific to this type of reconstruction is represented by abdominal hernia, occurring at the level of the donor area, due to the dissection of the *rectus abdominis* muscle [36]. A possible solution to this problem is the reconstruction of the abdominal wall using a non-absorbable mesh [37]. Regarding the postoperative aesthetic aspect and the rate of complications in the donor area, there are studies that support the superiority of this technique compared to the LD flap technique associated with implant [38]. However, it should not be neglected that moderate volume asymmetries are more easily accepted by the patient than asymmetries of the nipple–areola complex [39], therefore regardless of the reconstructive technique, particular attention should be paid to this aspect.

In the study published in 2013, Claro *et al.* compares the duration of the different techniques used for breast reconstruction surgery, the results showing that the use of implants can be accomplished in half of the time necessary to perform the intervention using TRAM or LD flaps, the latter associating similar intraoperative times [40]. Also, the material shows the increased rate of infectious complications associated with the TRAM reconstructive technique, which determined the increase in the number of readmissions in order to continue treatment [41].

The duration of the intervention has a significant impact on the rate of postoperative complications; the increase of the intraoperative time is associated with increased risk levels related to postoperative complications, one of the contributing factors being the high complexity of the surgical interventions requiring increased operating time. Another element is the excessive trauma of the tissues caused by prolonged exposure to external factors. The association between the duration of the surgery and the rate of postoperative complications was studied by Schaverien & Butler, in 2017 [41]; the authors have developed an interesting material showing that the risk of readmission increases by 50% for each hour that exceeds the interval of four hours in the case of reconstruction using the DIEP flap technique. Moreover, the necessity of secondary surgeries is doubled when complications are associated [42].

The comparative analysis of the reconstructive techniques shows that the rate of septic complications has the highest value in the case of breast reconstruction using the TRAM flap technique, followed by the LD flap technique, the lowest value being achieved by alloplastic reconstruction. This ranking can be caused as a result of complications occurring in the donor areas, as well as the fact that in this study TRAM flap reconstructions were

used in complicated cases where the implant extrusion was observed during the reconstruction protocol involving the expander-implant technique (Table 2).

Table 2 – Ranking of complications encountered during the current study compared to other research results from the specialized literature

Rank	Type of complications in the current study	Type of complications according to an international study (Claro <i>et al.</i> , 2013) [40]
1	Skin necrosis	Seroma
2	Superficial infection	Contracture Superficial infection Deep infection
3	Seroma	Extrusion
4	Dehiscence	Dehiscence Skin necrosis Expander failure

Formation of hematomas was also a complication encountered more frequently in the case of complex reconstructions with myocutaneous flaps [43], this being probably caused by the necessity of laborious flap dissections and subsequently the preparation of the receptor site.

Wound complications were observed as a result of all surgical techniques, their maximum rate being associated with reconstruction using the TRAM flap. The authors place this on account of complications in the donor area and its position which leads to the risk of tensioning the sutures during the mobilization of the patient. The association of septic complications, such as superficial infections is another factor that has contributed to the increase in the number of wound complications [44].

Expander malfunctions occurred in 3.28% of the patients that have suffered complications after breast reconstruction using the expander-implant technique and were generated by the rotation and detachment of the injection site [36].

The next section of the paper presents a comparative analysis between the research results achieved in the present study and the results obtained by Claro *et al.* (2013) in a particularly interesting study dedicated to understanding the phenomenon of complications related to breast reconstruction [40].

The comparative analysis referring to the implant extrusion rate determines similar values, 2.74% in the present study compared to 4.17% in the above-mentioned international study. The same situation occurs in case of capsular contracture with a rate of 5.48% in the present research compared to 6.25% in the second study. However, related to the present research, the authors predict a significant increase in the incidence rate of capsular contracture [45]; this is mainly caused by the large number of breast reconstructions involving silicone prostheses performed within the *National Mammary Reconstruction Subprogram*, which started in 2015. The relatively short time since the onset of the Program has not allowed a fair assessment of this parameter.

Regarding the comparative analysis of septic complications, there is a significant difference between the numbers of superficial infections identified in the two studies, the ratio being 2 to 1 (13.7% in the present study, respectively 6.25% in the international study). The results of the analysis referring to deep infections are relatively similar: a rate of 5.48% in the present study compared

to 6.25% in the foreign study. The authors consider the lack of standardization and the subjective appreciation as factors that have highly affected these parameters.

The results of the present study in relation with wound complications, indicate much higher values compared to the international study: a ratio of 5 to 1 related to dehiscence and a 10 to 1 ratio associated with marginal necrosis; these differences could be explained by the subjective assessment related to the degree of marginal wound trauma [46], as well as on the differentiation of the two types of complications involved in the analysis.

The ratio of malfunctions related to the tissue expander has similar values in both studies, a situation that can be explained by factory defects or incorrect handling.

The research presents the postoperative complications after surgical interventions performed in the aforementioned healthcare unit by plastic surgeons with different levels of training and expertise. Without a doubt, the rate of complications is significantly reduced in case of reconstruction surgeries performed by surgeons with extensive experience dedicated to this subdomain of plastic surgery [47].

The summarized presentation of the research results shows that skin necrosis is the most common postoperative complication, followed by superficial septic complications, formation of seromas, and wound dehiscence. The comparative analysis involving data obtained from an international specialized study, dedicated to the understanding of the phenomenon related to complications after breast reconstruction, indicates similar results in relation with superficial infections and wound dehiscences, the most frequent postoperative complication being the formation of seromas.

☒ Conclusions

Breast reconstruction using the expander-implant technique was the most commonly used method, the patients' choices being influenced by the lack of morbidity associated with the donor area and the access to information related to the classical principles of breast augmentation, a highly mediatized aspect in aesthetic surgery. After interpreting the results of the present study, the authors conclude that the atraumatic manipulation of the wound edges and the careful dissection of the myocutaneous flaps are essential in order to avoid complications, such as marginal necrosis. Another conclusion regarding this aspect is the necessity of developing objective criteria for the characterization of this parameter, thus creating the premises for the elaboration of comparative analyses related to international studies that provide statistically relevant data. In light of the findings, the authors consider that the analysis of the complications related to breast reconstruction is a topical subject that requires particular attention with the scope of reducing the emotional trauma suffered by the patients on their way to recovery. Without a doubt, further studies are needed, carried out on larger batches of patients, and that analyze the whole range of reconstructive surgical interventions related to the mammary region.

☒ Conflict of interests

The authors declare that they have no conflict of interests.

References

- [1] Warriar S, Tapia G, Goltsman D, Beith J. An update in breast cancer screening and management. *Womens Health (Lond)*, 2016, 12(2):229–239.
- [2] Wong G, Au E, Badve SV, Lim WH. Breast cancer and transplantation. *Am J Transplant*, 2017, 17(9):2243–2253.
- [3] Tenea-Cojan TŞ, Macovei A, Păun I, Costin AI, Georgescu CV, Georgescu CC, Vladu IM, Ene CG, Radu L. Assessment of hormonal receptor immunoexpression and Her2 status in invasive breast cancer after conservative and radical surgery. *Rom J Morphol Embryol*, 2018, 59(3):763–772.
- [4] Franceschini G, Martin Sanchez A, Di Leone A, Magno S, Moschella F, Accetta C, Masetti R. New trends in breast cancer surgery: a therapeutic approach increasingly efficacy and respectful of the patient. *G Chir*, 2015, 36(4):145–152.
- [5] Panchal H, Matros E. Current trends in postmastectomy breast reconstruction. *Plast Reconstr Surg*, 2017, 140(5S *Advances in Breast Reconstruction*):7S–13S.
- [6] Eltahir Y, Werners LL, Dreise MM, van Emmichoven IA, Jansen L, Werker PM, de Bock GH. Quality-of-life outcomes between mastectomy alone and breast reconstruction: comparison of patient-reported BREAST-Q and other health-related quality-of-life measures. *Plast Reconstr Surg*, 2013, 132(2):201e–209e.
- [7] Ganz PA. Psychological and social aspects of breast cancer. *Oncology (Williston Park)*, 2008, 22(6):642–646, 650; discussion 650, 653.
- [8] Tuttle TM, Burke EE. Bilateral mastectomy: doubling down on complications? *Ann Surg Oncol*, 2015, 22(11):3407–3408.
- [9] Bejinariu CG, Marinescu SA, Enescu MD. The Romanian National Breast Reconstruction Program – results and conclusions after 5 years. *Mod Med*, 2019, 26(1):23–30.
- [10] Helms RL, O'Hea EL, Corso M. Body image issues in women with breast cancer. *Psychol Health Med*, 2008, 13(3):313–325.
- [11] Sisco M, Du H, Warner JP, Howard MA, Winchester DP, Yao K. Have we expanded the equitable delivery of post-mastectomy breast reconstruction in the new millennium? Evidence from the National Cancer Data Base. *J Am Coll Surg*, 2012, 215(5):658–666; discussion 666.
- [12] Agha RA, Fowler AJ, Herlin C, Goodacre TE, Orgill DP. Use of autologous fat grafting for breast reconstruction: a systematic review with meta-analysis of oncological outcomes. *J Plast Reconstr Aesthet Surg*, 2015, 68(2):143–161.
- [13] Silva AK, Lapin B, Yao KA, Song DH, Sisco M. The effect of contralateral prophylactic mastectomy on perioperative complications in women undergoing immediate breast reconstruction: a NSQIP analysis. *Ann Surg Oncol*, 2015, 22(11):3474–3480.
- [14] Lemaine V. Bilateral prophylactic mastectomy and immediate breast reconstruction in high-risk women: the importance of health-related quality of life in decision making. *Ann Surg Oncol*, 2017, 24(9):2434–2435.
- [15] Marinescu SA, Zărescu O, Mihai IR, Giuglea C, Sinescu RD. An animal model of peripheral nerve regeneration after the application of a collagen–polyvinyl alcohol scaffold and mesenchymal stem cells. *Rom J Morphol Embryol*, 2014, 55(3):891–903.
- [16] Bijkerk E, van Kuijk SMJ, Beugels J, Cornelissen AJM, Heuts EM, van der Hulst RRWJ, Tuinder SMH. Breast sensibility after mastectomy and implant-based breast reconstruction. *Breast Cancer Res Treat*, 2019 Feb 12, 1–10.
- [17] Morrow M, Scott SK, Menck HR, Mustoe TA, Winchester DP. Factors influencing the use of breast reconstruction post-mastectomy: a National Cancer Database study. *J Am Coll Surg*, 2001, 192(1):1–8.
- [18] Razdan SN, Cordeiro PG, Albornoz CR, Disa JJ, Panchal HJ, Ho AY, Momoh AO, Matros E. National breast reconstruction utilization in the setting of postmastectomy radiotherapy. *J Reconstr Microsurg*, 2017, 33(5):312–317.
- [19] Oiz B. [Breast reconstruction and psychological benefit]. *An Sist Sanit Navar*, 2005, 28(Suppl 2):19–26.
- [20] Cano SJ, Klassen A, Pusic AL. The science behind quality-of-life measurement: a primer for plastic surgeons. *Plast Reconstr Surg*, 2009, 123(3):98e–106e.
- [21] Platt J, Baxter N, Zhong T. Breast reconstruction after mastectomy for breast cancer. *CMAJ*, 2011, 183(18):2109–2116.

- [22] Temple-Oberle C, Shea-Budgell MA, Tan M, Semple JL, Schrag C, Barreto M, Blondeel P, Hamming J, Dayan J, Ljungqvist O; ERAS Society. Consensus review of optimal perioperative care in breast reconstruction: Enhanced Recovery After Surgery (ERAS) Society recommendations. *Plast Reconstr Surg*, 2017, 139(5):1056e–1071e.
- [23] Kim DY, Lee TJ, Kim EK, Yun J, Eom JS. Intraoperative venous congestion in free transverse *rectus abdominis* musculocutaneous and deep inferior epigastric artery perforator flaps during breast reconstruction: a systematic review. *Plast Surg (Oakv)*, 2015, 23(4):255–259.
- [24] Fertsch S, Munder B, Hagouan M, Schulz T, Thamm O, Stambera P, Abu-Ghazaleh A, Schaberick J, Andree C. Immediate-DElayed AutoLogous (IDEAL) breast reconstruction with the DIEP Flap. *Chirurgia (Bucur)*, 2017, 112(4):387–393.
- [25] Mioton LM, Seth A, Gaido J, Fine NA, Kim JYS. Tracking the aesthetic outcomes of prosthetic breast reconstructions that have complications. *Plast Surg (Oakv)*, 2014, 22(2):70–74.
- [26] Nahabedian MY. Axillary advancement suture to minimize post-implantation deformity in implant-based breast reconstruction. *Aesthetic Plast Surg*, 2017, 41(5):1010.
- [27] Lagares-Borrego A, Gacto-Sanchez P, Infante-Cossio P, Barrera-Pulido F, Sicilia-Castro D, Gomez-Cia T. A comparison of long-term cost and clinical outcomes between the two-stage sequence expander/prosthesis and autologous deep inferior epigastric flap methods for breast reconstruction in a public hospital. *J Plast Reconstr Aesthet Surg*, 2016, 69(2):196–205.
- [28] Beugels J, Bod L, van Kuijk SMJ, Qiu SS, Tuinder SMH, Heuts EM, Piatkowski A, van der Hulst RRWJ. Complications following immediate compared to delayed deep inferior epigastric artery perforator flap breast reconstructions. *Breast Cancer Res Treat*, 2018, 169(2):349–357.
- [29] Farhangkhoe H, Matros E, Disa J. Trends and concepts in post-mastectomy breast reconstruction. *J Surg Oncol*, 2016, 113(8):891–894.
- [30] Wade RG, Marongiu F, Sassoon EM, Haywood RM, Ali RS, Figus A. Contralateral breast symmetrisation in unilateral DIEP flap breast reconstruction. *J Plast Reconstr Aesthet Surg*, 2016, 69(10):1363–1373.
- [31] Wu JD, Huang WH, Qiu SQ, He LF, Guo CP, Zhang YQ, Zhang F, Zhang GJ. Breast reconstruction with single-pedicle TRAM flap in breast cancer patients with low midline abdominal scar. *Sci Rep*, 2016, 6:29580.
- [32] Marinescu S, Florescu IP, Giuglea C, Lascăr I. Free tissue transfer in hand surgery – essential step in hand transplantation. *Chirurgia (Bucur)*, 2012, 107(1):79–88.
- [33] Bejinariu C, Apostolescu I, Marinescu S. Tratamentul cicatricilor postcombustionale de la nivelul sânelui. *Rom J Med Pract*, 2019, 14(1/64):62–65.
- [34] Spear SL, Clemens MW. *Latissimus dorsi* flap breast reconstruction. In: Neligan PC, Warren RJ (eds). *Plastic surgery*. 3rd edition, vol. 2, Saunders–Elsevier, Philadelphia, PA, 2012, 370–392.
- [35] Wilkins EG, Hamill JB, Kim HM, Kim JY, Greco RJ, Qi J, Pusic AL. Complications in postmastectomy breast reconstruction: one-year outcomes of the Mastectomy Reconstruction Outcomes Consortium (MROC) study. *Ann Surg*, 2018, 267(1):164–170.
- [36] Ascherman JA, Seruya M, Bartsich SA. Abdominal wall morbidity following unilateral and bilateral breast reconstruction with pedicled TRAM flaps: an outcomes analysis of 117 consecutive patients. *Plast Reconstr Surg*, 2008, 121(1):1–8.
- [37] Oliveira Junior FC, Mélega JM, Pinheiro AS, Destro C, Maciel PJ. Comparação entre a utilização da tela de Marlex em um e dois planos para a reconstrução da parede abdominal pós-TRAM. *Rev Bras Cir Plást*, 2010, 25(3 Suppl 1):49.
- [38] Kronowitz SJ, Robb GL, Youssef A, Reece G, Chang SH, Koutz CA, Ng RL, Lipa JE, Miller MJ. Optimizing autologous breast reconstruction in thin patients. *Plast Reconstr Surg*, 2003, 112(7):1768–1778.
- [39] Marinescu S, Bejinariu C, Boiangiu AM, Toma S, Badeana A. Breast reconstruction in a complex case of congenital breast asymmetry – case report. In: Georgescu A, Matei I, Ciura-Capotă I, Dumitrașcu D (eds). Abstracts of the XIth National Congress of the Romanian Society for Surgery of the hand, XIIth National Congress of the Romanian Society for Reconstructive Microsurgery & National Conference of the Romanian Association of Plastic Surgeons, 26–29 April 2017, Cluj-Napoca. Cluj Med, 2017, 90(Suppl 2):S56.
- [40] Claro F Jr, da Costa DV, de Souza Pinheiro A, Pinto-Neto AM. Complications in total breast reconstruction in patients treated for breast cancer: long-term comparative analysis of the influence of the technique, operative time, timing of reconstruction, and adjuvant treatment. *Rev Bras Cir Plást*, 2013, 28(1):85–91.
- [41] Schaverien MV, Butler CE. Complications in DIEP flap breast reconstruction after mastectomy for breast cancer: a prospective cohort study comparing unilateral and bilateral reconstructions. *Ann Surg Oncol*, 2017, 24(6):451–453.
- [42] Seth AK, Hirsch EM, Kim JY, Dumanian GA, Mustoe TA, Galiano RD, Fine NA. Hematoma after mastectomy with immediate reconstruction: an analysis of risk factors in 883 patients. *Ann Plast Surg*, 2013, 71(1):20–23.
- [43] Sinha I, Pusic AL, Wilkins EG, Hamill JB, Chen X, Kim HM, Guldbrandsen G, Chun YS. Late surgical-site infection in immediate implant-based breast reconstruction. *Plast Reconstr Surg*, 2017, 139(1):20–28.
- [44] Adkinson JM, Miller NF, Eid SM, Miles MG, Murphy RX Jr. Tissue expander complications predict permanent implant complications and failure of breast reconstruction. *Ann Plast Surg*, 2015, 75(1):24–28.
- [45] Sherman M. Capsular contracture: etiology, prevention, and treatment. In: Mugea TT, Shiffman MA (eds). *Aesthetic surgery of the breast*. Springer Verlag, Berlin–Heidelberg, 2015, 529–533.
- [46] Massenburg BB, Sanati-Mehrzy P, Ingargiola MJ, Rosa JH, Taub PJ. Flap failure and wound complications in autologous breast reconstruction: a national perspective. *Aesthetic Plast Surg*, 2015, 39(6):902–909.
- [47] Harcourt D, Paraskeva N, White P, Powell J, Clarke A. A study protocol of the effectiveness of PEGASUS: a multi-centred study comparing an intervention to promote shared decision making about breast reconstruction with treatment as usual. *BMC Med Inform Decis Mak*, 2017, 17(1):143.

Corresponding author

Cătălin-Gheorghe Bejinariu, MD, Department of Plastic and Reconstructive Surgery, “Carol Davila” University of Medicine and Pharmacy, “Bagdasar–Arseni” Emergency Clinical Hospital, 12 Berceni Highway, Sector 4, 041915 Bucharest, Romania; Phone +4021–334 30 25, e-mail: drbejinariu@gmail.com

Received: February 25, 2019

Accepted: May 7, 2019